

CYSTIC BLEB MANAGEMENT :A CASE REPORT

Adessa Rachma^{1*}, Maula Rifada²

¹Department Of Ophthalmology, Faculty Of Medicine, Padjadjaran University

²Indonesia National Eye Centre, Cicendo Eye Hospital

Email Korespondensi: Adessasuriadinata@Gmail.Com

Disubmit: 30 Januari 2024

Diterima: 16 Februari 2024

Diterbitkan: 01 Maret 2024

Doi: <https://doi.org/10.33024/mahesa.v4i3.14063>

ABSTRACT

Cystic Bleb Is An Abnormal Bleb Morphology Following Trabeculectomy Procedure. This Type Of Bleb Characterized By An Elevated, Thin, And Avascular Bleb Surface. Post-Operative Bleb Evaluation Needed To Be Done Thoroughly To Recognize And Prevent Further Complication Which Can Be Sight Threatening. Several Options Of Management Include Medical Therapy And Surgical Repair. To Report The Management Of Cystic Bleb. The Study Design Is A Case Report Study, Which Was Conducted At Indonesia National Eye Centre, Cicendo Eye Hospital, Bandung, Indonesia. Subject Of The Study Was A-17-Years-Old Female That Presented With Discomfort Sensation In The Right Eye, Which Previously Has Undergone Trabeculectomy Procedure With Antifibrotic Agent Application. Ophthalmological Examination Revealed A Cystic Bleb On The Right Eye. After Medical Therapy Was Given, The Symptoms Persist, Then The Cystic Bleb Was Surgically Repaired. Follow-Up Examination Showed An Improvement Of The Patient's Condition, Measured By No Further Complaint Of Discomfort Sensation, A Good Bleb Morphology, And A Stable Intraocular Pressure. Cystic Bleb Is One Of The Complication From Trabeculectomy Which Could Progress To Devastating Condition. Surgical Treatment Is Indicated If Symptoms Persist After Medical Management, Or In The Presence Of A Bleb Leakage.

Keywords: Antifibrotic, Cystic Bleb, Trabeculectomy

INTRODUCTION

Trabeculectomy Is A Widely Chosen Surgical Management Of Glaucoma That Stated As A Gold Standard Of Glaucoma Surgery. Since Its First Successful Report By Cairns In 1968, It Has Become The Most Frequently Performed Glaucoma Surgery. (Bhartiya Et Al., 2019) The Purpose Of Trabeculectomy Procedure Is To Increase The Outflow Of Aqueous Humor From Anterior Chamber To Subconjunctival Space. This Aqueous Humor Flow Will Create A Conjunctival Bleb. Bleb Formation Is One Of The Indicator Of Successful

Trabeculectomy That Can Be Assessed Intraoperatively (Fine, 2004); (Tanna Ap, Boland My, 2021).

During The Postoperative Examination, Bleb Morphology Should Be Thoroughly Assessed. Cystic Bleb Is A Condition Which Marked By An Elevated, Thin, And Avascular Wall Of The Bleb. This Abnormal Bleb Morphology Could Be Caused By The Use Of Antifibrotic Agents In Trabeculectomy. The Risk Of Bleb Leakage, Intraocular Hypotension, As Well As Infection, That May Threaten Vision Is

Increased By This Inadequate State Of The Bleb.(Fine C Laura, Chen Teresa, Grosskreutz C, 2004) Management Of Cystic Bleb Is Divided Into Surgical And Non-Surgical Options. The Choice Of Therapy Should Be Tailored To Each Patient's Condition (Trope, 2005); (Gosalia, 2018).

RESEARCH METHOD

The Method Use In This Article Is A Case Report Study. A Case Report Consist Of Detailed Report Of The Symptoms, Signs, Diagnosis, Treatment, And Follow-Up Of An Individual Patient. To Collect The Data, We Performed An In-Depth Interview, General And Ophthalmological Examination, Ancillary Test For Glaucoma, And Some Document Study. This Study Conducted At Indonesia National Eye Centre, Cicendo Eye Hospital, Bandung, Indonesia.

Subject Of This Study Was A 17-Years-Old Female That Presented With A Complaint Of A Sensation Of Discomfort In The Right Eye For The Past 2 Weeks. There Was No Associated Pain, Redness Of The Eye, Headache, Nausea, Vomiting, Or Blurred Vision. The Patient Had Undergone Trabeculectomy + Antifibrotic (5-Fluorouracil Or 5-Fu) In The Right Eye One Month Earlier. Currently, The Patient Was Using Timolol Maleate 0.5% Eye Drops In Both Eyes Twice A Day, Latanoprost Eye Drops In The Right Eye Once A Day, And Artificial Tears Eye Drops In Both Eyes Six Times A Day. The Patient Was Born Full-Term, And According To The Patient's Mother, The Right Eye Appeared Smaller Than The Left Eye Since Birth, With A Similar Complaint Reported In The Patient's Maternal Sibling. There Was No History Of Trauma Or Systemic Diseases.

General Examination Revealed The Patient In A Conscious And Compos Mentis State, With Mild Discomfort Was Noted. Other General Examinations Were Within Normal Limits. Ophthalmological Examination Showed A Visual Acuity Of 0.1 In The Right Eye And 3/60 In The Left Eye, With Self-Correction Of 0.15 And 0.8, Respectively. The Position Of The Eyeballs Appeared Orthotropic. The Movement Of Both The Right And Left Eyeballs Was Good In All Directions. Intraocular Pressure (Iop) Measured By Applanation Tonometry In The Right Eye Was 14 MmHg, And In The Left Eye Was 18 MmHg. Biomicroscopic Examination Of The Right Eye Revealed Calm Eyelids, Cystic Bleb On The Bulbar Conjunctiva With No Sign Of Leakage. Cornea Was Clear With A Diameter Of 9 Millimeters (Mm), Negative Fluorescein Staining, Anterior Chamber (Ac) Found To Have Shallow In Temporal Region With Negative Flare And Cells, Slightly Elongated Pupil, Peripheral Anterior Synechiae (Pas) In The 9-12 O'clock Direction, No Visible Peripheral Iridectomy, And Clear Lens. Direct And Consensual Light Reflexes Were Positive In The Right Eye, And Relative Afferent Pupillary Defect (Rapd) Was Negative. Fundus Examination Of The Right Eye Showed A Round Optic Disc With A Cup-To-Disc Ratio (Cdr) Of 0.5. Anterior Segment Examination Of The Left Eye Was Within Normal Limits. Indirect Gonioscopy Of The Right Eye Revealed An Intact Iridectomy Ostium With A Closed Anterior Chamber Angle, While The Left Eye Had An Open Angle. The Patient Was Then Diagnosed With Cystic Bleb Od (Right Eye) + Secondary Glaucoma Od + Suspected Anterior Segment Dysgenesis Od + Microcornea Od + Ocular Hypertension Os (Left Eye) + Compound Myopic Astigmatism Ods.

The Prescribed Management For The Patient Included Timolol Maleate 0.5% Eye Drops Twice A Day In Both Eyes, Latanoprost Eye Drops Once A

Day In The Right Eye, And Artificial Tears Eye Drops Six Times A Day In Both Eyes.

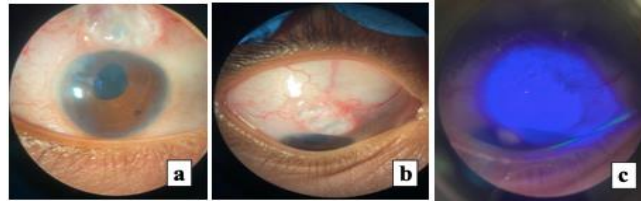


Figure 1. Pre-Operative Clinical Pictures. A) And B) Cystic Bleb, Microcornea, And Pas In The Right Eye. C) Fluorescein Staining On The Right Eye Showed No Bleb Leakage.

The Patient Returned For A Follow-Up One Month Later, Still Complaining Of Similar Symptoms Discomfort In The Right Eye. Ophthalmological Examination Revealed The Same Visual Acuity In Both Eyes As Before. The Position Of The Eyeballs Appeared Orthotropic, And Their Movement Was Good In All Directions. Intraocular Pressure Measured By Applanation Tonometry Was 21 Mmhg In The Right Eye And 20 Mmhg In The Left Eye. Biomicroscopic Examination Of Both Eyes And Indirect Gonioscopy Revealed Findings Similar To The Previous Examination. The Patient Was Diagnosed With Cystic Bleb Od + Secondary Glaucoma Od + Suspected Anterior Segment Dysgenesis Od + Microcornea Od + Ocular Hypertension Os + Compound Myopic Astigmatism Ods. Due To The Persistence Of Symptoms Despite Of Medical Therapy, The Patient Was Suggested To Undergo Surgical Repair Of The Cystic Bleb Of The Right Eye. The Same Medical Management As Before Was Continued, Except That Latanoprost Eye Drops In The Right Eye Were Discontinued. The Patient And Family Agreed For A Surgical Procedure To Repair The Right Eye Cystic Bleb With Scleral Patch Graft

Under General Anesthesia (Leung, 2007); (Wong, 2020).

The Surgery Began With Aseptic And Antiseptic Procedures, Draping, And Speculum Placement. A Traction Suture Was Placed At The 12 O'clock Cornea, And Peritomy Was Performed Around The Cystic Bleb, Following Its Shape And Towards The Superior Fornix. The Cystic Bleb Was Then Excised Using Wescott Scissors. Subsequently, At 1 O'clock, A Side Port Was Created, And Balanced Salt Solution Was Injected. After Complete Excision Of The Bleb, A Defect Was Observed In The Scleral Flap, Leading To The Decision To Perform A Scleral Patch Graft. Any Existing Bleeding Was Controlled Using Diathermy Cautery. The Donor Sclera's Size Was Adjusted To The Flap, And The Donor Sclera Was Sutured With 10.0 Nylon Thread In Five Stitches. The Scleral Graft Was Then Closed With Subtenon Layer Sutures First, Followed By Conjunctival Repair Using Conjunctival Advancement Technique. In The Final Stage Of The Surgery, Gentamicin Sulfate And Dexamethasone Were Injected Into The Inferonasal Subconjunctiva. The Patient Was Given Postoperative Therapy With Levofloxacin Eye Drops Six Times A Day, Prednisolone Acetate Eye Drops Six Times A Day,

Antibiotic Ointment Three Times A Day In The Right Eye, Oral Amoxicillin 3 Times 500 Mg Tablets,

And Oral Paracetamol 3 Times 500 Mg Tablets.

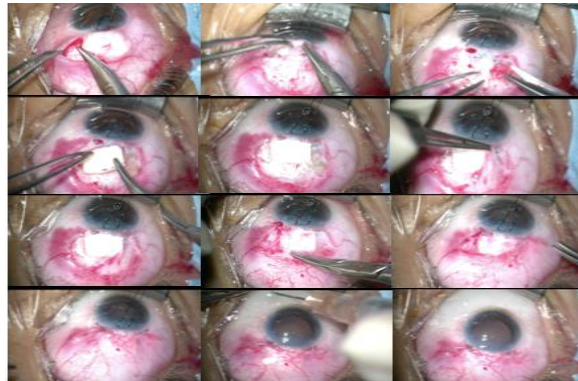


Figure 2. Bleb Repair And Scleral Graft Procedure Steps.

RESEARCH RESULT

One Day After The Operation, The Patient Complained Of Minimal Pain In The Right Eye. Ophthalmological Examination Revealed Visual Acuity Of 0.1 In The Right Eye And 3/60 In The Left Eye. Eye Movement Was Good In All Directions, Intraocular Pressure Measured By Applanation Tonometry Was 26 MmHg In The Right Eye And 21 MmHg In The Left Eye. Biomicroscopic Examination Of The Right Eye Showed Blepharospasm, Ciliary Injection, And

Subconjunctival Bleeding. The Graft And Sutures Were Intact On The Conjunctiva, And Other Anterior Segment Examinations Were Consistent With The Previous Findings. On The First Postoperative Day, The Patient Was Allowed To Be Discharged With Continued Oral And Topical Therapy, Including The Addition Of Timolol Maleate 0.5% Eye Drops Twice A Day In Both Eyes. The Patient Was Advised To Have A Follow-Up Appointment At The Glaucoma Clinic 7 Days Postoperatively.

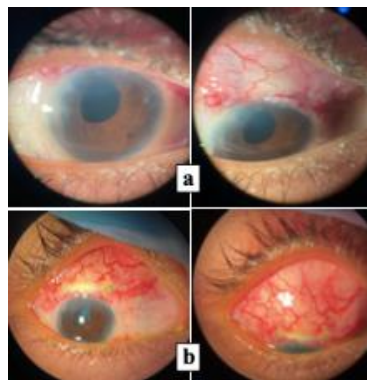

Figure 3. Postoperative Clinical Pictures Showed A Good Bleb Morphology. A) One Day After Surgery. B) One Week After Surgery.

One Week Postoperatively, The Patient Returned For A Follow-Up.

During The Visit, The Patient Complained Of Minimal Pain And

Redness In The Right Eye. Ophthalmological Examination Showed Visual Acuity Of 0.1 In The Right Eye And 3/60 In The Left Eye. Intraocular Pressure Measured By Applanation Tonometry Was 18 Mmhg In The Right Eye And 17 Mmhg In The Left Eye. Biomicroscopic Examination Revealed Ciliary Injection And Subconjunctival Bleeding. The Graft And Sutures Were Intact On The Conjunctiva,

With Some Grafts Only Partially Covered By Tenon's Capsule. Seidel's Test Results Were Negative. Other Anterior Segment Examinations Were Similar To Previous Findings. The Patient Was Prescribed Prednisolone Acetate Eye Drops, Gradually Tapered Each Week (5 Times/4 Times/3 Times A Day) In The Right Eye And Timolol Maleate 0.5% Eye Drops Twice A Day In Both Eyes.

DISCUSSION

The Success Of Trabeculectomy Can Be Evaluated Based On Several Clinical Indicators, Including Intraocular Pressure (Iop), Anterior Chamber Depth (Acd), And Bleb Morphology. (Tanna Ap, Boland Mv, 2021) A Well-Functioning Conjunctival Bleb Should Facilitate Aqueous Humor Outflow Without Obstruction From Fibrotic Tissue. The Wound Healing Process After Trabeculectomy Is Mediated By Various Proinflammatory Cytokines, Including Tumor Growth Factor, Tumor Necrotizing Factor-A (Tnf-A), And Macrophage Chemoattractant Proteins-1 (Mcp-1), Which Activate The Fibrotic Tissue Formation Cascade. (Trope, 2005) Inflammatory Responses Can Lead To Excessive Fibrotic Tissue Formation, Posing A Risk Of Bleb Failure. The Activity Of Fibroblasts Can Be Influenced By Antifibrotic Agents, Commonly Used In Trabeculectomy Procedures. Two Frequently Used Antifibrotics Are Mitomycin-C (Mmc) And 5-Fluorouracil (5-Fu). (Yamanaka Et Al., 2015)

Clinical Assessment Of The Bleb Is Performed Using Slit-Lamp Microscopy. (Trope, 2005) Various Classification Systems Are Employed To Assess Post-Trabeculectomy Bleb Morphology. These Systems Aim To Simplify Assessment, Predict Early Bleb Failure, And Guide Follow-Up

Plans And Management. Among The Classification Systems, The Indiana Bleb Appearance Grading Scale (Ibags) And Moorfields Bleb Grading System (Mbgs) Are Commonly Used. Both Systems Assess Parameters Such As Bleb Area, Height, Vascularity, Seidel Test, And Additional Parameters Like Subconjunctival Hemorrhage In Mbgs. An Ideal Bleb Should Be Diffuse With Minimal Elevation And Have Vascularity Similar To The Healthy Surrounding Conjunctiva. Abnormal Variations Include Cystic, Dymorphic Or Encapsulated, And Flat Blebs. Cystic Blebs Are Characterized By Elevated Surfaces With Thin Avascular Conjunctival Walls (Desai, 2020); (Hoffmann Et Al., 2020)

The Mechanism Of Cystic Bleb Formation Is Explained By Khaw's "Ring Of Steel" Theory, Which Describes The Formation Of A Fibrotic Ring At The Bleb's Edge, Creating A Localized Cystic Area. The Formation Of The Fibrotic Ring Is Associated With Differences In Fibroblast Activity At The Central And Edge Regions Of The Bleb Influenced By Antifibrotic Use. Fibroblast Activity Is Found To Be Higher At The Bleb's Edge And Lower At The Central Bleb. A Study In 2018 By Al-Mugheiry And Broadway Reported A Cystic Bleb Incidence Of

24% In Patients Using 5-Fu And 12% With Mmc. Currently, The Risk Of Cystic Bleb Formation With Mmc Is Considered Greater Than With 5-Fu.(Trope, 2005); (Bar-David & Blumenthal, 2018); (Al-Mugheiry T, 2018).

Another Known Factor Influencing The Formation Of Cystic Blebs Is The Choice Of Conjunctival Flap Technique. Fornix-Based Conjunctival Flap (Fbcf) Is More Commonly Used Than Limbus-Based Conjunctival Flap (Lbcf) Because It Is Considered To Provide Better Results. Lbcf Has The Disadvantage Of Interfering With The Healing Process In The Limbal Region, Thereby Increasing The Risk Of Thinner Blebs. Another Consideration Is The Application Area Of Antifibrotic, Which Can Be More Freely Performed On Fbcf, Resulting In Less Fibrosis And The Formation Of Diffuse Blebs.(Trope, 2005)(Wells Ap, Brunce C, Cordeiro Mf, 2003)(Khaw Pt, Chiang M, Shah P, 2022)

Clinically, Patients With Cystic Blebs May Experience Various Complaints, Ranging From Discomfort, Irritation, To Drooping Eyelids Due To Mechanical Ptosis. Cystic Blebs Can Cause Cosmetic Dissatisfaction In Patients Because The Scars Appear Different From The Surrounding Conjunctiva. The Fragile And Thin Walls Have The Risk Of Leakage. Bleb Leakage Can Occur Spontaneously, Due To Eyelid Friction During Blinking Or Scraping Of The Bleb Wall By Eyelash Hairs. Besides Spontaneous Occurrences, Bleb Leakage Can Also Be Triggered By Trauma. Complications Of Bleb Leakage Include Ocular Hypotony And Infection In The Form Of Blebitis, Which Can Develop Into Endophthalmitis; Both Complications Threaten Vision. Clinically, Patients May Complain Of Watery Eyes And Fluctuating Vision Due To Hypotony.

Asymptomatic Bleb Leakage Can Occur In Small-Sized Leaks. Detailed Examination Using A Slit Lamp Microscope And Seidel Test Is Necessary To Identify Bleb Leaks.(Fine C Laura, Chen Teresa, Grosskreutz C, 2004)(Trope, 2005)(Khaw Pt, Chiang M, Shah P, 2022) In This Case, The Patient Presented With Irritation In The Left Eye After Undergoing Trabeculectomy And Antifibrotic 5-Fu Operation. The Surgical Report Indicated That The Chosen Conjunctival Flap Technique Was Limbus-Based, And Both Of These Factors Contributed To The Risk Of Forming Cystic Blebs. Ophthalmological Examination Revealed A Cystic Bleb Without Leakage.

Management Of Cystic Blebs Is Tailored To The Patient's Clinical Presentation. Cystic Blebs Without Leakage Causing Discomfort Can Be Observed, With Additional Patient Education. Education Should Include The Recognition Of Signs Of Infection Such As Redness, Watery Eyes, Pain, And Decreased Visual Acuity. Artificial Tears And Lubricating Ointments Can Alleviate Discomfort Or Irritation. The Use Of A Bandage Contact Lens Is Not Recommended Due To Inadequate Protection From The Elevated Bleb Surface And An Increased Risk Of Infection.(Trope, 2005)(Khaw Pt, Chiang M, Shah P, 2022) In Patients With Persistent And Significant Complaints After Medical Approaches, As In This Case, Surgical Management Becomes An Option. The Success Rate Of Bleb Repair Is Quite High, At 77%.

The Surgical Repair Technique For Blebs, With Or Without Leakage, Follows The Same Steps. Cystic Blebs Are Excised Thoroughly After Peritomy Of The Surrounding Conjunctiva. Subsequently, After Exposing The Scleral Flap, An Assessment Is Made To Determine If

There Are Defects Or Leaks. Leaks In The Scleral Flap Require Repair With Donor Sclera, Pericardium, Or Autologous Tenon Tissue. Conjunctival Repair Can Then Be Performed Using Various Techniques. The Patient's Conjunctival Condition And The Initial Size Of The Bleb Determine The Suitable Technique. Conjunctival Advancement Is A Technique Used When The Conjunctiva Is In Good, Elastic Condition, And The Bleb Is Small. Conjunctival Pedicle And Autologous Conjunctival Flap Are Used For Larger Blebs Or In Cases Where The Conjunctiva Around The Inflamed And Fragile Bleb.(Trope, 2005)(Sehgal, 2017)(O'rourke M, Moran S, Collins N, 2021) In This Case, A Leak Was Found In The Scleral Flap, And A Scleral Patch Graft From A Donor Was Performed. Conjunctival Repair Was Done Using The Conjunctival Advancement Technique, Chosen Because The Surrounding Conjunctiva Was Still Elastic In The Young Patient.

Dysmorphology Of Blebs Can Be Prevented With Proper Surgical Planning Tailored To The Patient's Condition. The Use Of Antifibrotics, Especially Mmc, Carries Significant Risks In The Formation Of Cystic Blebs, So Its Indications Need Careful Consideration. The Concentration And Duration Of Application Of These Agents Also Affect The Antifibrotic Effect Produced. When Applying Antifibrotics, It Is Recommended To Use Non-Fragmenting Sponges (Polyvinyl Alcohol-Based Sponges) Rather Than Methylcellulose Sponges. The Conjunctival Edge Needs To Be Protected From Direct Exposure To Antifibrotic Agents To Avoid Interfering With The Healing Of The Potential "Ring Of Steel."(Fine C Laura, Chen Teresa, Grosskreutz C, 2004)

CONCLUSION

In Conclusion, Cystic Blebs Are An Abnormal Variation In The Shape Of Conjunctival Blebs After Trabeculectomy, Characterized By Elevated Bleb Surfaces, Thin Walls, And Avascularity. In This Case Report, There Were Risk Factors For The Formation Of Cystic Blebs, Namely, The Use Of Antifibrotic Agents In Trabeculectomy And Limbus-Based Conjunctival Flap (Lbcf) Technique. In This Case Report, After Adequate Medical Therapy Symptoms Still Persist, Hence Surgical Repair Was Planned. The Procedure Involving Cystic Bleb Excision And Scleral Patch Graft Which Resulted In A Good Outcome In This Patient, Marked By Stable Intraocular Pressure And A Well-Formed Bleb Morphology.

REFERENCES

- Al-Mugheiry T, B. D. (2018). Trabeculectomy Bleb Morphology Type Of Antimetabolite And Other Predictive Factors For The Development Of Adverse Thin Cystic Blebs. *Iorvs Arvo*, 9(3).
- Bar-David, L., & Blumenthal, E. Z. (2018). Evolution Of Glaucoma Surgery In The Last 25 Years. *Rambam Maimonides Medical Journal*, 9(3), E0024. <https://doi.org/10.5041/Rmmj.10345>
- Bhartiya, S., Dhingra, D., & Shaarawy, T. (2019). Revisiting Results Of Conventional Surgery: Trabeculectomy, Glaucoma Drainage Devices, And Deep Sclerectomy In The Era Of Migs. *Journal Of Current Glaucoma Practice*, 13(2), 45-49. <https://doi.org/10.5005/Jp-Journals-10078-1248>
- Belyea, D. A., Dan, J. A., Stamper, R.

- L., Lieberman, M. F., & Spencer, W. H. (1997). Late onset of sequential multifocal bleb leaks after glaucoma filtration surgery with 5-fluorouracil and mitomycin C. *American journal of ophthalmology*, 124(1), 40-45.
- Desai, K., & Krishna, R. (2002). Surgical management of a dysfunctional filtering bleb. *Ophthalmic Surgery, Lasers and Imaging Retina*, 33(6), 501-503.
- Fine C Laura, Chen Teresa, Grosskreutz C, P. L. (2004). Management And Prevention Of Thin, Cystic Blebs. *Int Ophthalmol Clin*, 44(1), 29-42.
- Fink, A. J., Boys-Smith, J. W., & Brear, R. (1986). Management of large filtering blebs with the argon laser. *American journal of ophthalmology*, 101(6), 695-699.
- Gosalia, N. R., Dikopf, M. S., Lim, J. I., Lin, A. Y., Tu, E. Y., & Aref, A. A. (2018). Cyst Masquerading as Inadvertent Bleb After a Scleral-Fixated Intraocular Lens in Marfan Syndrome: A Case Report. *Ophthalmology and Therapy*, 7, 437-441.
- Gollakota, S., Balijepalli, P., Richhariya, A., & Senthil, S. (2020). Case report: Blebophthalmos: proptosis due to a massive bleb following implant surgery in refractory paediatric glaucoma. *BMJ Case Reports*, 13(5).
- Hoffmann, E. M., Herzog, D., Wasielica-Poslednik, J., Butsch, C., & Schuster, A. K. (2020). Bleb Grading By Photographs Versus Bleb Grading By Slit-Lamp Examination. *Acta Ophthalmologica*, 98(5), E607-E610. <https://doi.org/10.1111/Aos.14335>
- Khaw Pt, Chiang M, Shah P, H. C. (2022). Glaucoma Filtration Surgery: Indication, Technique, And Complication. In Albert And Jakobiec/S Principles And Practice Of Ophthalmology (Pp. 2821-2839). Springer.
- Krishnacharya, P. S. (2013). Tenon's cyst presenting as a long-term complication following incision cataract surgery. *Case Reports in Medicine*, 2013.
- Leung, C. K. S., Yick, D. W. F., Kwong, Y. Y. Y., Li, F. C. H., Leung, D. Y. L., Mohamed, S., ... & Lam, D. S. C. (2007). Analysis of bleb morphology after trabeculectomy with Visante anterior segment optical coherence tomography. *The British journal of ophthalmology*, 91(3), 340.
- O'rourke M, Moran S, Collins N, D. A. (2021). Bleb Reconstruction Using Donor Scleral Patch Graft For Late Bleb Leak And Hypotony. *European Journal Of Ophthalmology*, 31(3), 1039-1046.
- Sehgal, V. (2017). Techniques Of Bleb Repair. *Delhi Journal Of Ophthalmology*, 28(1), 13-15. <https://doi.org/10.7869/Djo.283>
- Tanna Ap, Boland Mv, G. J. (2021). Basic And Clinical Science Course. In *Glaucoma* (Pp. 256-270). American Academy Of Ophthalmology.
- Trope, G. (2005). *Glaucoma Surgery* (1st Ed.). Taylor & Francis.
- Wells Ap, Bruce C, Cordeiro Mf, K. P. (2003). Cystic Bleb Formation And Related Complications In Limbus-Versus Fornix-Based Conjunctival Flaps In Pediatric And Young Adult Trabeculectomy With Mitomycin C. *American*

- Academy Of Ophthalmology, 110(11), 2192-2197.
- Wilson, M. R., & Kotas-Neumann, R. (1994). Free conjunctival patch for repair of persistent late bleb leak. *American journal of ophthalmology*, 117(5), 569-574.
- Wong, Y. L., & Shankar, V. (2020). Case report: Trauma-induced filtering bleb formation and blebitis 40 years following a penetrating eye injury. *BMJ Case Reports*, 13(6).
- Yamanaka, O., Kitano-Izutani, A., Tomoyose, K., & Reinach, P. S. (2015). Pathobiology Of Wound Healing After Glaucoma Filtration Surgery. *Bmc Ophthalmology*, 15(1). <https://doi.org/10.1186/s12886-015-0134-8>