



CASES OF MEIGE'S SYNDROME CONTROLLED FOLLOWING ADMINISTRATION OF LOW-DOSE BOTULINUM TOXIN TYPE-A: A SERIAL CASE SERIES

Retno Jayantri Ketaren¹, Jacqueline Tasha Margono², Reza Stevano³

Correspondence: retno.ketaren@uph.edu

¹Neurology Department, Siloam Hospitals Lippo Village, Tangerang, Banten, Indonesia

²Neurology Department, Siloam Hospitals Lippo Village, Tangerang, Banten, Indonesia

³Faculty of Medicine, Pelita Harapan University, Tangerang, Banten, Indonesia

Article History:

Received: April 3, 2023

Accepted: May 19, 2023

Published: July 1, 2023

Cite this as: Vancouver style
Ketaren R J, Margono J T,
Stevano R. Cases Of Meige's
Syndrome Controlled Following
Administration Of Low-Dose
Botulinum Toxin Type-A: A
Serial Case Series. Magna
Neurologica. 1 (2) July 2023:41-
43.,
10.20961/magnaneurologica.v1i2.
700

ABSTRACT

Background: Meige syndrome is a form of cranial dystonia characterised by blepharospasm and oromandibular dystonia, with a twice-fold higher prevalence in women as compared to men. The definitive pathophysiology underlying Meige syndrome remains unknown, but some studies have postulated the role of striatal dopaminergic activity. Currently, no curative treatments are available for Meige syndrome, but non-specific modalities include oral agents such as anti-cholinergics, dopaminergics, and benzodiazepines. Botulinum toxin Type-A (BoNTA) constitutes an effective treatment option in cases of Meige syndrome refractory to oral management.

Case summary: We report three cases of female patients, age 42, 57, and 61 years, presenting with complaints of blepharospasm and oromandibular dystonia. Low-dose BoNTA injections were administered, 10 units total weekly divided into the orbicularis oculi, corrugator supercilii, frontalis, procerus, nasalis, zygomaticus, mentalis, dan risorius, and orbicularis oris areas. Following repeated administrations of BoNTA injections, the three patients no longer experience symptoms up till now.

Conclusion: The authors report that low-dose BoNTA injections are effective in ameliorating dystonic symptoms associated with Meige syndrome, with low incidences of side effects.

Keywords: Meige's syndrome, Low Dose, Botulinum Toxin Type-A, Oromandibular Dystonia, Treatment

Introduction

Meige syndrome, also known as "Breughel syndrome", "Wood syndrome", "Blepharospasm plus", "Cranial segmental dystonia", and "Cranio-cervical segmental dystonia", is a form of cranial dystonia which characterized by blepharospasm and oromandibular dystonia. The syndrome was first described by a French neurologist named Henry Meige in 1910.¹

Meige's syndrome is generally found in women aged 30 to 70 years. Clinical symptoms that are often found in this syndrome includes blepharospasm accompanied by difficulty opening the mouth, teeth grinding, jaw deviation, and lip spasms. The muscles that are most frequently affected are the masseter, temporalis, and platysma muscles. Symptoms may worsen with talking, chewing and biting.^{2,3}

Special characteristics of the dystonia in Meige's syndrome can be relieved by sensory stimuli also called the sensory tricks. More than half of patients with dystonia have one or more sensory tricks; in the form of sleeping, relaxing, talking, pulling the upper eyelids, blowing cheeks, walking, exposed to cold water, yawning, drinking, chewing gum, or pressing the chin and other facial areas.^{2,3,4}

The pathophysiology of Meige's syndrome is still not definitively known. However, several studies have suggested

the pathophysiology of dystonia involving dopaminergic activity in the striatum or the presence of cholinergic abnormalities. Momentarily, there is no curative therapy for Meige's syndrome, and treatment options consist of non-specific modalities including oral medication, injection Botulinum Toxin Type-A (BoNTA), and Deep Brain Stimulation (DBS).⁴ BoNTA injection is a common therapeutic option used in cases of dystonia. However, the availability of these drugs in Indonesia is still limited and with costly price. Therefore, BoNTA must be used judiciously and efficiently to maximize its benefits.⁵ We reported three patients with Meige's syndrome who achieved complete remission of dystonic symptoms after treatment with low-dose BoNTA injections.

Case Report

Our first patient was a 42-year-old woman who came with difficulty of opening both eyelids with increased blinking frequency in the past 1 year accompanied by oromandibular movements which makes it difficult for her to speak, eat, or drink. The patient had tried oral medication as follows: Clobazam 1x10 mg, Trihexyphenidyl 3x2mg, and Clonazepam 1x2 mg. Unfortunately, they did not give any significant effect. The patient chose BoNTA injection for further treatment. The patient got BoNTA

(onabotulinumtoxinA) injection for the first time at 4 injection sites in the orbicularis oculi muscle, and 1 injection site in the procerus muscle with a total of 10 units due to limited funds and drug availability. Injections in the following week were carried out with a maximum dose of 10 units divided into the mental and risorius areas. Furthermore, injections are given alternately every other week with a limited dose of 10 units. The patient received injections for 11 weeks and on the last meeting patient stated improvements. On our latest meeting she was given 2 injections in the risorius area with a total dose of 4 units. This patient did not have any side effects to complain.

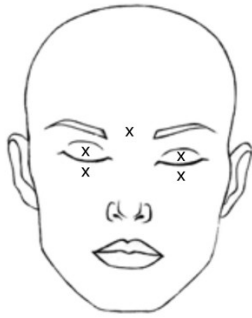


Figure 1. Initial dose given to the first patient.
X = 2 ml BoNTA injection.

Our second patient was a 57-year-old woman who came with difficulty of opening both eyes in the past 3 months. She complained excessive blinking which has occur this past 5 years. On physical examination movement in the oromandibular area were found. Initially the patient was given 10 units of BoNTA (onabotulinumtoxinA) injections in orbicularis oculi, risorus, frontalis, and mentalis. The injections were then given to other muscle such as nasalis, and orbicularis oris alternatively on the following other weeks. The patient complained hyperlacrimation as a side effect that occurred one day following an injection on orbicularis oculi. On our 10th meeting, the patient had no more complaints.

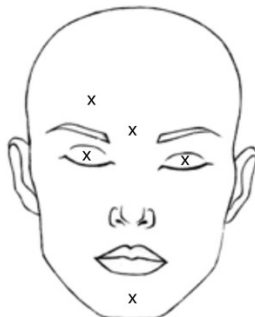


Figure 2. Initial dose given to second patient.
X = 2 ml BoNTA injection.

The third patient is a 61-year-old woman with a similar complaint, namely difficulty opening both eyes since the last 8 months accompanied by involuntary movements of the oromandibular. On the first meeting the patient was given 10 units of BoNTA (onabotulinumtoxinA) injections in

orbicularis oculi, procerus, and orbicularis oris. The injections were given alternatively every other week to other muscles such as corrugator supercili, nasalis, risorius, zygomaticus and mentalis. The patient received only 2 units on each procerus and zygomaticus on her 8th meeting. At a follow-up of 1 year (first patient), 4 years (second patient), and 2 years (third patient) after the last injection, the three patients have no more complaints.

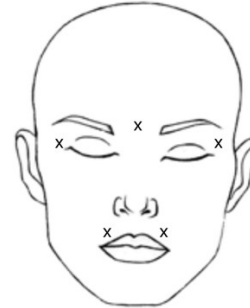


Figure 3. Initial dose given to the third patient.
X = 2 ml BoNTA injection.

Musculus	Week 1			Week 2			Week 3			Week 4			Week 5			Week 6			Week 7			Week 8			Week 9			Week 10			Week 11		
	1	2	3	1	2	3	1	2	3	1	2	3	1	2	3	1	2	3	1	2	3	1	2	3	1	2	3	1	2	3	1	2	3
Orbicularis oculi lateral sinistra	x	x	x																														
Orbicularis oculi lateral dextra	x	x	x																														
Orbicularis oculi medial sinistra	x			x	x	x																											
Orbicularis oculi medial dextra	x			x	x	x																											
Orbicularis oris superior																																	
Orbicularis oris inferior																																	
Frontalis sinistra				x			x			x			x			x																	
Frontalis dextra				x			x			x			x			x																	
Procerus	x	x	x	x	x	x	x	x	x	x	x	x	x	x	x	x	x	x	x	x	x	x	x	x	x	x	x	x	x	x	x	x	x
Mentalis sinistra				x																													
Mentalis dextra							x			x			x			x			x			x			x			x			x		
Risorius sinistra										x			x			x			x			x			x			x			x		
Risorius dextra																																	
Zygomaticus sinistra													x			x			x			x			x			x			x		
Zygomaticus dextra																x			x			x			x			x			x		

Table 1. Injection sites evolution.

Discussion

BoNTA injection is an effective therapeutic option for dystonic patients who are unresponsive to oral therapy such as anticholinergics, benzodiazepines, GABA receptor agonists, dopamine receptor agonists, anticonvulsants, and vesicular monoamine transporter 2 inhibitors.⁴ BoNTA is a potent neurotoxin produced by Clostridium botulinum which can cause muscle paralysis by inhibiting the release of acetylcholine at synaptic junctions, causing local chemodeneration. The therapeutic effect of BoNTA can be felt immediately and reaches a maximum therapeutic effect in 3-6 days^{6,7,8} and has a 76-100% success rate in hemifacial spasms, with an average repair duration ranging from 2.6 to 4 months. The maximum therapeutic effect that our patients felt reaches 2 weeks and might be caused due to the lower dose that were given in comparison to other journals. Another systematic review, assessing BoNTA therapy for blepharospasm in the adult population has concluded that BoNTA periocular injection is more effective than placebo for alleviating the severity of symptoms.¹⁰ Knowledge of the functional anatomy of the areas involved in the injection is essential for the effective use of BoNTA injections. It is crucial to maximize the effect of the neurotoxin on the target muscles, as well as preventing the complications that can arise due to the impact of the toxin on adjacent structures.¹¹ Complications from BoNTA injections

are common and tend to be mild and transient. However, the complications that arise can still interfere with the patient's comfort and capacity to carry out daily activities. Several systematic reviews found that the most common side effects of BoNTA injection for cervical dystonia consisted of local muscle weakness, dysphagia, dry throat, and dysphonia.¹² Side effects that might appear after BoNTA injection for Meige's syndrome including lagophthalmos, facial droop, lip droop, as well as hyperlacrimation. Side effects can occur due to inaccurate injection site or excessive doses of neurotoxins.¹³

A study by Jochim et al. showed the average dose for effective therapy for patients with Meige syndrome was 35.6 ± 21.8 units with a recommended dose of 1.25-2 units at each injection site.¹⁴ To date, there is no consensus being published regarding standard practice of BoNTA injection, including the dilution ratio of BoNTA toxin, dose per injection, total dose per muscle, or the number of injections at each site. All parameters may vary between clinicians.¹⁵ Moreover, a study by Sättilä et al. who investigated differences in low and high doses of BoNTA in spastic or dystonic disorders found that clinical improvement was achieved even with lower doses, indicating that the use of higher doses does not always produce better results. Sättilä et al. also found a higher incidence of adverse events in the high-dose group.¹⁶ Our patients were given 10 units of BoNTA injections per appointment, far from the recommended dose by Jochim et al.¹⁴ Nonetheless, the dose given remained effective in controlling the symptoms experienced, where the benefit of the response is maintained at 1-4 years after the last injection, with a mild hyperlacrimation as side effect or no side effect.

Conclusion

BoNTA injection is an effective therapeutic option in cases of Meige syndrome. However, due to limited drug availability and uneconomical prices, BoNTA must be used wisely and efficiently to maximize its benefits and minimize complications. In this case series, we establish that low-dose BoNTA injections are effective in controlling dystonic symptoms in Meige's syndrome, with low complication rates and long-term benefits.

Acknowledgement

The author has nothing to disclose and did not receive any funding source for writing the research.

References

- Pandey S, Sharma S. Meige's syndrome: History, epidemiology, clinical features, pathogenesis and treatment. *Journal of the Neurological Sciences*. 2017;372:162–70.
- Meige syndrome. U.S. National Library of Medicine; [cited 2022 Mar 24]. Available from: <https://pubmed.ncbi.nlm.nih.gov/30020730/>
- Gautam P, Bhatia MS, Kaur J, Rathi A. Meige's syndrome. *Ind Psychiatry J*. 2016;25(2):232-233. doi:10.4103/0972-6748.207853
- Ma H, Qu J, Ye L, Shu Y, Qu Q. Blepharospasm, Oromandibular Dystonia, and Meige Syndrome: Clinical and Genetic Update. *Frontiers in Neurology*. 2021Mar29;12. doi:10.3389/fneur.2021.630221
- Francisco GE: Botulinum toxin: Dosing and dilution. *Am J Phys Med Rehabil* 2004;83(suppl):S30–S37.
- Weiner WJ, Tolosa E. Hyperkinetic movement disorders: Handbook of clinical neurology (series editors: Aminoff, Boller and Swaab). Amsterdam: Elsevier Science; 2014.
- Chaudhry N, Srivastava A, Joshi L. Hemifacial spasm: The past, present and future. *Journal of the Neurological Sciences*. 2015;356(1-2):27–31.
- Duarte GS, Rodrigues FB, Castêlão M, Marques RE, Ferreira J, Sampaio C, et al. Botulinum toxin type A therapy for hemifacial spasm. *Cochrane Database of Systematic Reviews*. 2020;2020(11).
- Batisti JP, Kleinfelder AD, Galli NB, Moro A, Munhoz RP, Teive HA. Treatment of hemifacial spasm with botulinum toxin type A: eJective, long-lasting and well tolerated. *Arquivos de Neuropsiquiatria* 2017;75(2):87-91.
- Bilyk JR, Yen MT, Bradley EA, Wladis EJ, Mawn LA. Chemodenervation for the Treatment of Facial Dystonia: A Report by the American Academy of Ophthalmology. *Ophthalmology*. 2018;125(9):1459. Epub 2018 Apr 10.
- Hassell TJW, Charles D. Treatment of Blepharospasm and Oromandibular Dystonia with Botulinum Toxins. *Toxins (Basel)*. 2020 Apr 22;12(4):269. doi: 10.3390/toxins12040269. PMID: 32331272; PMCID: PMC7232182.
- Castêlão M, Marques RE, Duarte GS, Rodrigues FB, Ferreira J, Sampaio C, Moore AP, Costa J. Botulinum toxin type A therapy for cervical dystonia. *Cochrane Database Syst Rev*. 2017;12:CD003633. Epub 2017 Dec 12.
- Rowe F, Noonan C. Complications of botulinum toxin a and their adverse effects. *Strabismus*. 2009 Oct-Dec;17(4):139-42. doi: 10.3109/09273970903303860. PMID: 20001507.
- Jochim A, Meindl T, Huber C, Mantel T, Zwirner S, Castrop F, et al. Treatment of blepharospasm and Meige's syndrome with abo- and onabotulinumtoxinA: long-term safety and efficacy in daily clinical practice. *Journal of Neurology*. 2019Oct19;
- Albanese A. Terminology for preparations of botulinum neurotoxins: what a difference a name makes. *JAMA*. 2011;305(1):89.
- Heli Sättilä; Anne Kotamäki; Matti Koivikko; Ilona Autti-Rämö (2006). Low- and High-Dose Botulinum Toxin A Treatment: A Retrospective Analysis. , 34(4), 0–290. doi:10.1016/j.pediatrneurol.2005.08.03.