



## CASE REPORT

## OPEN ACCESS

# NEUROLOGICAL COMPLICATIONS AFTER COVID 19 VACCINATIONS: SERIAL CASE REPORT

Intan Permata Sari<sup>1</sup>, Hanindia Riani Prabaningtyas<sup>1</sup>*Correspondence: dr.inpersa@gmail.com*<sup>1</sup> Department of Neurology, Faculty of Medicine, Universitas Sebelas Maret / Dr. Moewardi General Hospital.**Article History:**

Received: October 12, 2022

Accepted: October 12, 2022

Published: January 1, 2023

**Cite this as: Vancouver style**  
Sari I P, Prabaningtyas H R.  
*Neurological Complications After Covid 19 Vaccinations: Serial Case Report. Magna Neurologica. 1 (1) January 2023:9-12.*

**ABSTRACT**

**Background:** COVID-19 vaccination has been carried out worldwide, with more than 5 million dose of vaccine delivered. Although declared safe, there are cases of neurological disorders after the Covid 19 vaccination.

**Cases:** In the first case, a 20-year-old male came with decrease level of consciousness, 4 days after receiving the first dose of COVID 19 vaccine with Sinovac vaccine. MRI Brain shows acute disseminated encephalomyelitis (ADEM). In the second case, a 50-year-old male with seizures and decreased consciousness after receiving first dose of COVID-19 vaccination with Sinovac vaccine, 10 days before admission. Non contrast CT Scan and brain contrast MRI Brain revealed cerebral edema. In the third case, an 18-year-old woman had seizures and decreased consciousness one month after the first dose of COVID 19 vaccination with Sinovac. Contrast Head MRI showing focal leptomeningitis. In the fourth case, a 30-year-old male with slurred speech and right-sided weakness. Three months before admission, he had fever, headache, and tingling of the right limbs a few days after the first dose of COVID 19 vaccination with Sinova MRI Brain Contrast shows ADEM lesion

**Discussion:** The mechanism of neurological disorders concerning COVID 19 vaccination is still unclear. Neurological complications after vaccination weaken the effort of vaccination, but can be used as a precaution and assess prognosis while waiting for further confirmation from large epidemiological studies and meta-analyses. Until now, it is believed that the COVID-19 vaccine has important benefits and is a hope for ending the COVID-19 pandemic.

**Keywords:** Acute Demyelinating Encephalomyelitis, COVID 19 vaccination, Neurological Complication

## Introduction

COVID-19 vaccination program has been carried out worldwide, with a total of more than 5 million doses were given until the end of 2021. Some neurological side effects of COVID-19 vaccination are observed. Functional neurological disorders could be observed as impaired consciousness, limb weakness, seizures, or sensory disturbances. One of the most life-threatening condition following vaccination is meningoencephalitis and acute disseminated encephalomyelitis (ADEM). Meningoencephalitis incidence after COVID-19 vaccination was reported on several case report.<sup>1</sup>

Neurological disorder after vaccination are often caused by impaired brain tissue function, rather than brain structure disorders.<sup>2</sup> Acute disseminated encephalomyelitis (ADEM) is an inflammatory disease resulting in central nervous system demyelination. Around three-quarters of ADEM cases occur after infection, in particular viral infection, or immunization.<sup>3</sup> ADEM following viral infection often manifests as multifocal neurologic deficits. Several publications suggest an association of vaccination with autoimmune demyelination, where around 5% of ADEM events are related to varicella, rabies, measles, mumps, rubella, influenza, hepatitis B, diphtheria, pertussis, and

tetanus immunizations. Symptoms of ADEM were developed after 2-31 days after vaccination, and spontaneous improvement were observed after treatment with corticosteroids.<sup>4</sup>

Although declared safe, there were cases of neurological disorders after COVID-19 vaccination. In this case report, we report patients with ADEM and meningoencephalitis after receiving COVID-19 vaccination.

## Case Report

### First Case

A 20 years old male came to the ER with decreased consciousness, 4 days after he received the first dose of the COVID-19 Sinovac vaccine. His family found that he sleeps more, and very hard to be woken up. He also had slurred speech, fever, and persistent hiccups. On physical examination, vital signs were unremarkable. He was compos mentis with Glasgow Coma Scale (GCS) E3V4M5, and no meningeal sign were observed. He had right abducent nerve paresis, lower motor neuron (LMN) right facial nerve paresis, and bilateral Babinsky's pathological reflex. On laboratory examination, we found increasing D dimer (3754 mg/ml) and positive ANA IF, supporting the diagnosis of

Sjogren's Syndrome. Brain contrast MRI revealed supratentorial intraaxial lesions in bilateral basal ganglia, frontotemporal lobes, mesencephalon, and pons, suggesting acute disseminated encephalomyelitis.

He received IV methyl prednisolone 1000 mg q.d. for 5 days, IV Arixtra 2.5 mg q.d, and chlorpromazine 25 mg q.d. After the 7 day of treatment, his condition started to improved, he began to open his eyes spontaneously and make eye contact. After the 14 day of treatment, his consciousness improved and he began to understand commands. Day 16 days of treatment, he was fully aware, and he was discharge after 18 day of treatment.

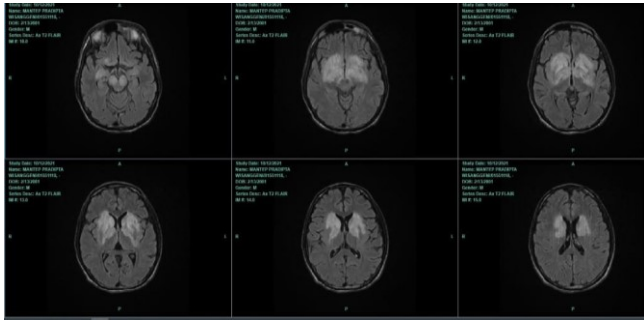


Figure 1. Axial brain contrast MRI on T2-FLAIR sequence

### Second Case

A 50-year-old man with seizures and loss of consciousness came to the ER. Two days before admission, he felt fever and headache, and started to looked confused and became difficult to communicate with. Then he looked weak, refused to eat, looked sleepy, and tended to sleep. These symptoms occurred 10 days after receiving the first dose of COVID-19 vaccination, with Sinovac/Biofarma vaccine. He also had general seizure, and during the seizure, he looked up, bit his tongue, and urinate, and the seizure lasted around 1 minute. On physical examination, we found hypotension (100/60mmHg) and hyperthermia (38°C). On neurological examination, GCS was E2V2M5, neck stiffness (+), Brudzinski I (+), Brudzinski II (+), cranial nerves were unremarkable, and no motor lateralization was found. On hematologic examination, we observed leukocytosis (19.000/ul), and lumbar puncture showed increasing number of cells (44/ul), with domination of MN (98%). Cerebral edema was observed on non-contrast head CT Scan and brain contrast MRI Brain contrast.

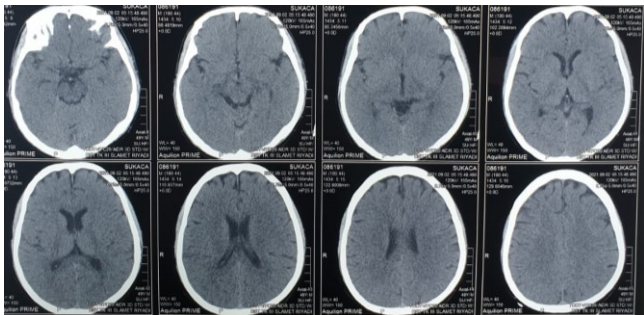


Figure 2. Non-contrast CT Scan of the Axial Section

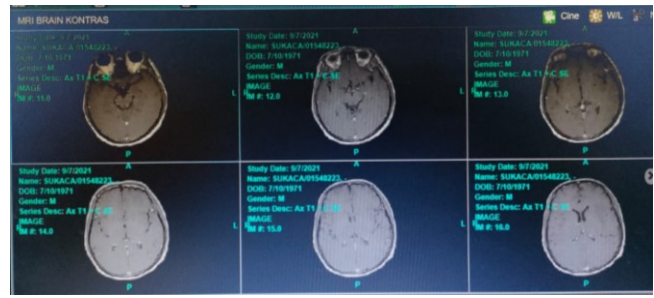


Figure 3. MRI of the Head with Axial section T1 + Contrast

He received IV Ceftriaxon 2 gr b.i.d, IV Aciclovir 750 mg t.i.d, IV Phenytoin 100 mg b.i.d, IV Dexamethasone 10 mg t.i.d, IV Paracetamol 1 gr b.i.d, IV Omeprazole 40 mg b.i.d, and IV Diazepam 10 mg if convulsions. After the 7th day of treatment, the patient level of consciousness is improved, he was able to open his eyes spontaneously and make eye contact with other people. On day 12 he was fully conscious and able to communicate well. On the 15th day of treatment, the patient was discharge from our facility.

### Third Case

An 18-year-old woman, came with with seizures and loss of consciousness. Initially she had fever for a few days, seemed weak, difficult to communicate with and tended to sleep. On the next day she began to have seizures, around 5-6 times a day. During the seizure, both arms move, both eyes glance up, could not communicated, and between seizures, she was unconscious. These symptoms were arised 1 month after the patient was vaccinated against the first dose of COVID-19 with the Sinovac vaccine. On physical examination, she was hypotensive (105/54 mmHg) and hyperthermic (38°C). On neurological examination, we found decreased level of consciousness with GCS E3V3M5, cranial nerves and meningeal sign were unremarkable. On motor examination, hypertonus, hyperreflexes, and positive pathological reflexes were found in all four extremities. From the results of hematologic laboratory examinations, we found leukocytosis (22,400/ul) and from the results of a lumbar puncture, we found that the dominance of MN cells (67%). On non-contrast head CT scan, we found and Contrast Head MRI showed gyral enhancement in the bilateral frontoparietooccipital region indicating focal leptomeningitis.

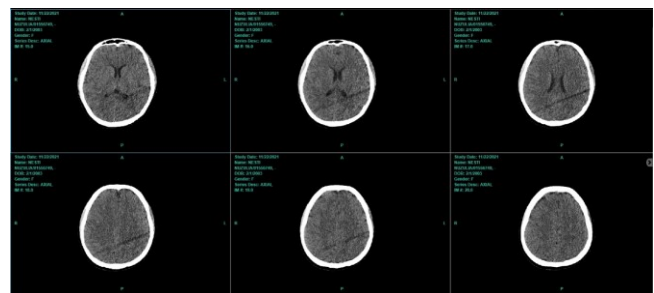
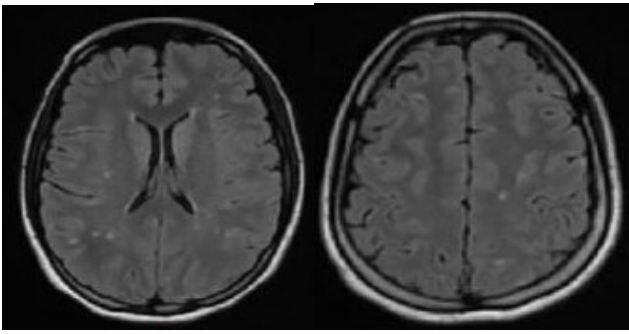


Figure 4. CT scan of the head non-contrast axial section



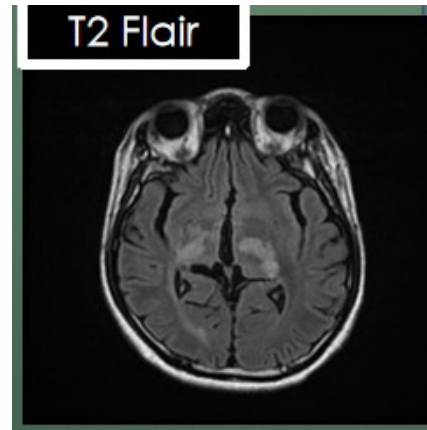
**Figure 5.** MRI of the head Contrast axial section of T2 Flair sequence

He received loading dose of Phenytoin 800 mg, Midazolam 5 mg/hour, propofol titrated dose 10-15cc/hour, Maintenance MgSO<sub>4</sub> 20% 6 grams in 500 cc NaCl 0.9%, 50cc/hour until the 12th day of treatment, IV Ceftriaxone 2 gr b.i.d for 7 days followed by Ceftazidim injection 2 gr b.i.d for 7 days, IV Dexamethasone 10 mg q.i.d tapering off, IV Omeprazole injection 40 mg b.i.d, IV Paracetamol injection 1gr b.i.d, and Depakote 250 mg b.i.d. On the 10th day of treatment, midazolam and propofol were discontinued, and therapy was added with IV Phenytoin 100mg b.i.d. On the 12th day of treatment, she free from seizures and her level consciousness began to improve, she could open his eyes spontaneously and make eye contact with people around her. On the 18th day of treatment, she was able to communicate even though the response was slow.

#### **Fouth Case**

A 30-years-old man came with slurred speech and weakness of the right limb. Slurred speech, with drooping mouth and weakness of the right limb had been felt for one month before admission, and worsened 2 weeks before admission. Around 3 months earlier, he suffered from fever and headache a few days after the first dose of COVID-19 vaccination with Sinovac vaccine. He also felt tingling in his right limb. On physical examination, vital signs were found within normal limits. On neurological examination, he was compos mentis, with paresis of cranial nerves VII, and right XII UMN, dysarthria, right hemiparesis, and right hemiparesthesia. Hematologic laboratory examinations were unremarkable. On CSF fluid analysis, PMN cell dominance was found (55%). MRI brain contrast revealed multiple supratentorial intraaxial lesions, with indistinct borders, irregular edges on the bilateral thalamus indicating Acute Demyelinating Encephalomyelitis.

He received IV methylprednisolone 500 mg b.i.d, for 3 days, and physiotherapy. After showing clinical improvement on the 8th day of treatment, he was discharged from the hospital.



**Figure 6.** MRI Head Axial contrast

## **Discussion**

In this case series, we report patients with neurological disorders after the COVID-19 vaccination. The first and fourth cases are to post COVID-19 vaccination ADEM cases. ADEM is a central nervous system (CNS) demyelinating disease that usually occurs as a result of infection or after immunization, usually characterized by fever associated with the onset of neurological disorders. Although its rare, ADEM could result as complication associated with vaccination. ADEM following immunization appears to be more common after the first dose, rather than after the second dose of vaccine. Symptoms suggestive of central nervous system involvement include encephalopathy, focal cortical signs (aphasia, alexia, agraphia), cranial nerve palsy, visual field defects, motor weakness, sensory disturbances, tendon reflex disorders, cerebellar dysfunction (ataxia, dysmetria, nystagmus). In previous studies, it was stated that ADEM occurred within 1 month of immunization, but until now there has been no consensus on the duration between immunization and the onset of ADEM. ADEM-associated vaccinations, potentially resulting from an immune response to vaccine components, depend on the characteristics of the individual immune response of the person being vaccinated, the type of vaccine, the amount of chemicals present in the vaccine, and other factors. Cerebellar dysfunction (ataxia, dysmetria, nystagmus). In previous studies it was stated that ADEM occurred within 1 month of immunization, but until now there has been no consensus on the duration between immunization and the onset of ADEM. ADEM-associated vaccinations, potentially resulting from an immune response to vaccine components, depend on the characteristics of the individual immune response, the type of vaccine, the amount of chemicals present in the vaccine, and other factors.<sup>5</sup> On CSF examination, ADEM usually marked by lymphocytic pleocytosis and increased protein. MRI gold standard imaging modality for ADEM. Abnormality on MRI will appear after 5-14 days after onset. Cerebral lesions are usually disseminated, but on 10-30%, it may show as solitary lesions. The lesion pattern in ADEM is often scattered, multifocal, or extensive white matter lesions, with extensive lesions accounting for more than 50% of the total white matter volume. Although none of the features on MRI are typical for ADEM, diffuse, focal or multifocal (disseminated) inflammation and demyelination in the



subcortical and deep cortical white matter areas and sometimes also in the gray matter (often in the gray matter), and thalamus which enhanced on contrast administration is indicating ADEM lesion. However, recent studies shows that ADEM lesions will appear after a few weeks and only some lesions will appear enhanced, and may not appear enhanced. It is recommended that follow-up MRI be performed at intervals of at least 6 months to confirm the diagnosis of ADEM by which time there should be partial or complete resolution, and no new lesions. If a new lesion is found, it will lead to the diagnosis of MS. To date, there are few clinical studies and there is no standard therapy for ADEM after vaccination or for other causes. Current treatment options are based solely on empirical clinical evidence. When ADEM is diagnosed after excluding other causes, treatment should be initiated as soon as possible. Current therapy is focused on immunosuppression and immunomodulation. Treatment options include corticosteroids, plasma exchange, and intravenous immunoglobulin (IVIG). The prognosis is complete recovery, and in 50% to 75% cases spontaneous improvement is the expected outcome, with minimal residual deficits. Estimated duration of rehabilitation is about 1 to 6 months. Predictors of poor outcome include old age, female, degree of functional impairment, protein level in CSF, spinal involvement, peripheral nerve damage, and poor response to corticosteroids.<sup>6</sup>

There are limited reports of encephalitis associated with the COVID-19 vaccine. In the second and third cases leading to meningoencephalitis. Data from The Centers for Disease Control and Prevention (CDC) Vaccine Adverse Event Reporting System reported that until September 2021, there were 66 cases of post-COVID-19 vaccination encephalitis. In the cases reported, latency periods of 10 days to 6 weeks. Until now, it is difficult to confirm whether the vaccine causes encephalitis. However, one important finding is that there was clinical improvement in patients treated with steroids. The mechanism that causes the various neurological syndromes associated with COVID-19 vaccination is still unclear, but it is thought that the mechanism is the same as infection with the SARS-CoV-2 virus, i.e. through direct viral neuronal injury or secondary hyperinflammatory syndrome in the host. There is still ongoing discussion regarding neurological disorders after COVID 19 vaccination. With the increased production of neuroinflammatory mediators, it is speculated that there is a cytokine storm associated with brain dysfunction, where the mechanism is not limited to COVID 19 infection, but in fact vaccination has potential trigger autoimmunity by molecular mimicry mechanism.<sup>7</sup>

The four cases of neurological disorders that occurred after the COVID 19 vaccination above have similarities, where all four are the first dose of vaccination and use the same type of vaccine, Sinovac. Sinovac is a vaccine produced by the Chinese Biopharmaceutical Company, Sinovac Biotech, under another name Coronavac. This type of vaccine is a whole virus vaccine that uses the inactivated SARS-Cov-2 virus. Inactivated viruses are not able to infect the body but are able to trigger the formation of body immunity.<sup>8</sup> In a trial study on the effectiveness of this vaccine, it was stated that the efficacy of this vaccine to prevent hospitalization due to

COVID 19 (WHO severity score 4) was 100%, with 10 cases found in the placebo group and zero in the vaccine group, and cases of death from COVID 19 found in the placebo group.<sup>9</sup> However, from several reports of neurological disorders after vaccination, it is hoped that it does not weaken the effort of vaccination, but can be used as a precaution and assess prognosis while waiting for further confirmation from large epidemiological studies and meta-analyses. Until now, it is believed that the COVID-19 vaccine has important benefits and is a hope for ending the COVID-19 pandemic.<sup>9</sup>

## Conclusion

In this paper, we reported rare case of Acute disseminated encephalomyelitis (ADEM) and meningoencephalitis after COVID-19 vaccination

## Acknowledgement

The authors would like to thank to Director of Dr. Moewardi General Hospital, Surakarta, Indonesia for permission of data collection.

## References

1. Ercoli T, Lutzoni L, Orofino G, Muroli A, Defazio G. Functional neurological disorder after COVID-19 vaccination. *Neurol Sci.* 2021 Oct;42(10):3989–90.
2. Patone M, Handunnetthi L, Saatci D, Pan J, Katikireddi SV, Razvi S, et al. Neurological complications after first dose of COVID-19 vaccines and SARS-CoV-2 infection. *Nat Med.* 2021 Dec;27(12):2144–53.
3. Kania K, Ambrosius W, Tokarz Kupczyk E, Kozubski W. Acute disseminated encephalomyelitis in a patient vaccinated against SARS-CoV-2. *Ann Clin Transl Neurol.* 2021 Oct;8(10):2000–3.
4. Ahmad SA, Salih BK, Hama Hussein KF, Mikael TM, Kakamad FH, Salih AM. Aseptic meningoencephalitis after COVID-19 vaccination: A case report. *Annals of Medicine and Surgery.* 2021 Nov;71:103028.
5. Torisu H, Okada K. Vaccination-associated acute disseminated encephalomyelitis. *Vaccines.* 2019 Feb;37(8):1126–9.
6. Huynh W, Cordato DJ, Kehdi E, Masters LT, Dedousis C. Post-vaccination encephalomyelitis: Literature review and illustrative case. *Journal of Clinical Neuroscience.* 2008 Dec;15(12):1315–22.
7. Mike Nafizahni. Types of Covid-19 Vaccines: What Are The Differences? [Internet]. 2022. Available from: <https://corona.jakarta.go.id/en/article/kenalan-dengan-vaksin-vaksin-covid-19-yuk>
8. WHO. Background document on the inactivated vaccine Sinovac-CoronaVac against COVID-19. 2021; Available from: [https://www.who.int/publications/i/item/WHO-2019-nCoV-vaccines-SAGE\\_recommendation-Sinovac-CoronaVac-background-2021.1](https://www.who.int/publications/i/item/WHO-2019-nCoV-vaccines-SAGE_recommendation-Sinovac-CoronaVac-background-2021.1)
9. Kobayashi Y, Karasawa S, Ohashi N, Yamamoto K. A case of encephalitis following COVID-19 vaccine. *Journal of Infection and Chemotherapy.* 2022 Feb;S1341321X2200496.