

ISSN : 1978 - 3019

HAYATI

Journal of Biosciences

Vol. 21 No. 1 March 2014



ISSN: 1978-3019 (printed)
EISSN: 2086-4094 (electronic)

HAYATI

Journal of Biosciences

Vol. 21 No. 1 March 2014

Accredited by Indonesian Directorate General of Higher Education No. 80/DIKTI/Kep/2012

Granted for Internationalization Program of Scientific Journal by Directorate General of Higher Education No. 773/D3/LL/2009

MANAGING EDITOR
Utut Widyastuti

CHIEF EDITOR
Berry Juliandi

ONLINE JOURNAL MANAGER
Kanthi Arum Widayati

ENGLISH EDITOR
Miftahudin

EDITORIAL BOARD

Achmad Farajallah, Alex Hartana, Antonius Suwanto, Aris Tri Wahyudi, Bambang Suryobroto, Darjono, David Nedwell, Dyah Perwitasari, Ence Darmo Jaya Supena, Emmanuel Paradis, Erin Phelps Riley, Iman Rusmana, Kanthi Arum Widayati, Koji Nakamura, Lisdar Idwan Sudirman, Miftahudin, Nunik Sri Ariyanti, Ocky Karna Radjasa, Rebecca Johnson, Rika Raffiudin, Sri Budiarti, Tri Heru Widarto, Tsukasa Sanosaka, Tukirin Partomihardjo, Utut Widyastuti, Yamato Tsuji, Yasumasa Bessho, and Youji Nitta

TECHNICAL EDITORS

Mafrikhul Muttaqin, Puji Rianti, and Rika Indri Astuti

BUSINESS MANAGER

Sulistijorini

PUBLISHER

Indonesian Society for Biology and
Department of Biology, Faculty of Mathematics and Natural Sciences, Bogor Agricultural University

EDITORIAL ADDRESS

HAYATI Journal of Biosciences
Department of Biology, Faculty of Mathematics and Natural Sciences
Bogor Agricultural University, Darmaga Campus, Bogor 16680, Indonesia
Phone/Fax: +62-251-8421258; E-mail: hayati_j_biosci@cbn.net.id
<http://journal.ipb.ac.id/index.php/hayati>

HAYATI Journal of Biosciences publishes articles, short communications, and invited reviews in bioscientific fields such as development, biotechnology, biodiversity and environmental issue. The articles cover wide range of organisms including virus, microbes, fungi, plants, animals, and human. Published four times a year: March, June, September, and December.

SUBSCRIPTION RATES - not including shipping and handling

Subscriber	One year	
	Overseas (USD)	Indonesian (Rp)
Personal	50	250.000,00
Institution/library	75	350.000,00

SHORT COMMUNICATION

Haemozoin Detection in Mouse Liver Histology Using Simple Polarized Light Microscope

DWI RAMADHANI*, SITI NURHAYATI, TUR RAHARDJO

*Center for Technology of Radiation Safety and Metrology, National Nuclear Energy Agency of Indonesia
Jalan Lebak Bulus Raya No. 49, Kotak Pos 7043, Jakarta 12070, Indonesia*

Received February 25, 2013/Accepted September 6, 2013

The presence of malarial pigment (haemozoin) due to *Plasmodium* infection is a common histopathological effect in mouse liver. Previous research showed that by using a polarized light microscope, researchers were better able to detect haemozoin in mouse liver histology section. Thus, the aim of this research was to compare the haemozoin area observed by a conventional vs. simple polarized light microscope by using image processing analysis. A total of 40 images produced from both conventional light microscope and simple polarized light microscope were collected. All images were analyzed using ImageJ 1.47 software to measure the haemozoin areas. Our results showed that non birefringent haemozoin and birefringent haemozoin area was significantly different. This was because when using conventional light microscope the brown area that contained images of non birefringent haemozoin images also contained Kupffer cells which appeared as the same brown color as haemozoin. In contrast, haemozoin gave bright effect and can be easily differentiated with Kupffer cells in the birefringent haemozoin images. This study concluded that haemozoin detection in mouse liver histology using a simple polarized light microscope was more accurate compared to that of conventional light microscope.

Keywords: haemozoin, liver histology, mouse, microscope, polarization

INTRODUCTION

Malaria is a serious global disease and a leading cause of morbidity and mortality in tropical and subtropical countries. It affects between 350 and 500 million people worldwide and causes more than one million deaths each year (Syaifudin *et al.* 2011). Malaria is caused by protozoan parasites of the genus *Plasmodium* (Hisaeda *et al.* 2005) and its common histopathological effect due to *Plasmodium* infection is the presence of haemozoin in the liver (Baheti *et al.* 2003). Haemozoin is a heme polymer produced by the parasite as a result of hemoglobin breakdown inside the red blood cells (RBC) of the host. The lysis of red blood cells during infection results in release of merozoites with this heme pigment, which are phagocytized by circulating monocytes, neutrophils and resident macrophages (Sullivan & Meshnick 1996; Egan 2003). The amount of haemozoin in tissues increases over the duration of infection, therefore the amount of pigment correlates with the chronicity of the lesion (Silva *et al.* 2011). As a result of haemozoin

accumulation, liver histology is reveals congestion with brown or black pigmentation (Baheti *et al.* 2003).

Examination of haemozoin in liver histology is usually manually identified under microscope. It is commonly observed in association with late stage parasitic infection or as an indicator of previous (including treated) infection. Because it contains a birefringent (doubly refracting) substance, haemozoin is highly visible when viewed using crossed polarized light (Lawrence & Olson 1986). The haemozoin in human placental histological specimens using polarizing microscope was more sensitive than conventional light microscope (Romagosa *et al.* 2004). However, the haemozoin detection using polarized light microscope can produce false results. This is because dust and dirt on the slide may produce a birefringence similar to that of haemozoin. However such false positive results can be avoided by double checking the pigment containing cells for parasites by using light microscopy (Romagosa *et al.* 2004).

Maude *et al.* (2009) devised a simple method for adapting a conventional light microscope for polarized light microscopy. They used a pair of gray or black polarizing sunglasses and a small

*Corresponding author. Phone: +62-21-7513906/7659511,
Fax: +62-21-7657950, E-mail: dhani02@btan.go.id

additional piece of polarizing material that had been cut out of from a plastic polarizing lens or a polarizing test strip. The researchers placed a black polarizing sunglass on the top of light source of microscope and a piece of polarizing material placed on the top of thick blood smear slide from a patient with severe malaria. This apparatus was able to can successfully identify haemozoin inside the slide (Maude *et al.* 2009). Here in this study, we adapted those techniques using a conventional light microscope for polarized light microscope to detect haemozoin area in the mouse (*Mus musculus* sp.) liver section histology. The aim of this research was to compare the measurements of haemozoin area obtained using a conventional light microscope vs. a simple polarized light microscope by using image processing analysis.

MATERIALS AND METHODS

Polarized Light Microscope. A Nikon Biophot microscope was used as a conventional light microscope. The equipments required for adapting Nikon Biophot to become a polarized light microscope were a linear polarizing sheet (45 x 35 mm) (Polar Pro) and commercial circular polarizing filter (CPL) 58 mm (Hoya Pro1) for Digital Single Lens Reflex (DSLR) Camera. The CPL filter 58 mm was placed on the top of the microscope light source and the linear polarizing sheet was placed on the top of liver histology slide. The slides were examined under 40X objective lens with maximum brightness (Figure 1). The CPL filter was rotated in a clockwise direction until it reached the position where the object appeared to be most dark. The difference between light and dark was approximately in 45° of rotation. The angle at which the object appears darkest was noted (Kramer *et al.* 2001).

Mouse (*Mus musculus* sp.) Liver Histology. Mouse (*Mus musculus* sp.) liver histology slides

were made in 7 µm thickness using hematoxylin eosin (HE) stain and were obtained from the Nuclear Biomedical Laboratory in the Center for Technology of Radiation Safety and Metrology, National Nuclear Energy Agency of Indonesia. Mice were inoculated with the irradiated *Plasmodium berghei* of an ANKA strain at a dose of 150 Gy and were kept for 24 days before proceeding to liver histological study.

Image Acquisition. A Nikon Biophot microscope attached to Nikon D3000 digital single lens reflects (DSLR) camera system was used to capture the images of the blood smear slides. Images were captured at a resolution of 1936 x 1296 pixel and saved as JPEG files. The first image was captured using the adapted polarized light microscope, whereas the second image was captured using the same setting but after removal of the linear polarizing sheet and CPL filter. A total of 20 images were collected using simple polarized and conventional light microscope.

Image Analysis. A macro program was developed in ImageJ 1.47 for measuring the birefringent haemozoin area in mouse liver histology. The algorithm of macro program can be divided into the following several sequential steps (Figure 2). The first step was to split the images channels into green, blue and red channels. The second step was to invert the green channel image to detect the haemozoin area using thresholding methods. The last step was to measure the haemozoin area and determine the outlined haemozoin area in the images. The haemozoin area in images captured using the conventional light microscope was measured by using an ImageJ 1.47 plugin previously developed (unpublished data). To obtain the measurement of the areas presented in micrometer (µm) the Set Scale command in ImageJ must be employed. First an image of a microscope stage micrometer under the same microscope magnification that




Figure 1. CPL filter 58 mm on top of the microscope light source (blue arrow) (left) and a linear polarizing sheet on the top of a liver histology slide (blue arrow) (right).

used to capture the haemozoin must be obtained. Then with the straight line selection tool, we drew a line that corresponded to known distance in the microscope stage micrometer image. Subsequently, the known distance and unit of measurement was entered in the Set scale command dialog. ImageJ will automatically fill in the Distance in Pixels field based on the length of the line (Papadopolus *et al.* 2007).

Statistical Analysis. Birefringent and non birefringent haemozoin areas from 20 images were compared using *t*-test analysis. Significant level used in this research is 0.05 (5%), differences with *p*-value less than 0.05 were considered to be significant.

RESULTS

Birefringent and Non Birefringent Haemozoin Area Measurement. The average area of birefringent and non birefringent haemozoin observed in our samples (of 20 images) were $2843.47 \pm 779.49 \mu\text{m}^2$ and 4101.151 ± 2053.75

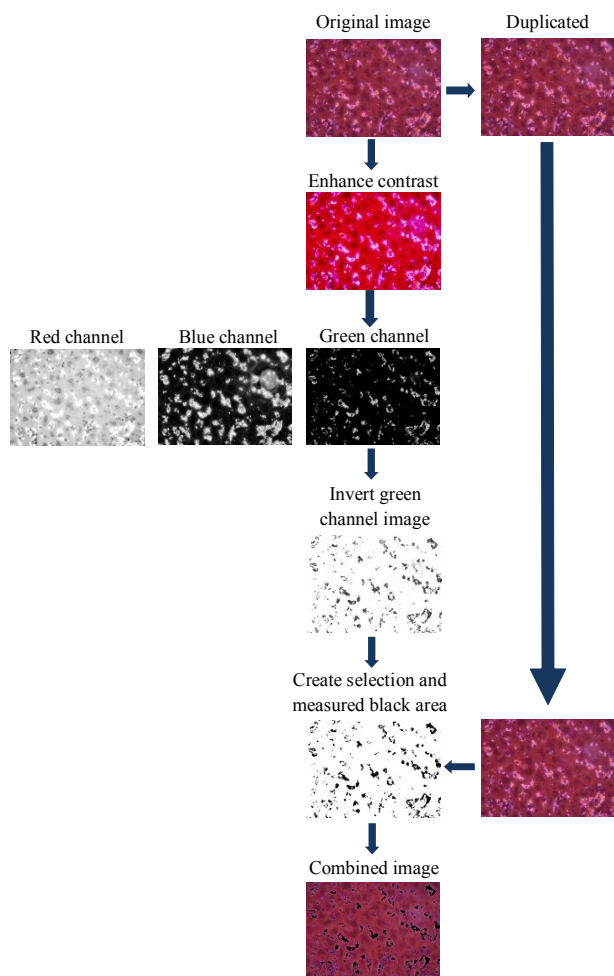


Figure 2. ImageJ Macro flowchart for measure birefringent haemozoin area.

μm^2 , respectively. Scatter plots of the data points showed that the linear relation between birefringent and non birefringent haemozoin area was quite low ($r = 0.0785$; Figure 3). Statistical analysis using *t*-test showed that there was a significant different between the area of birefringent and non birefringent haemozoin ($P = 0.011$).

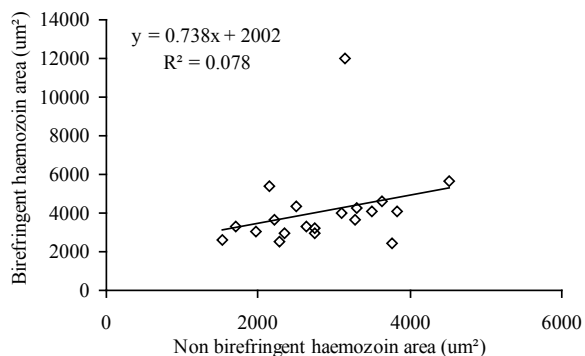


Figure 3. Scatter plots comparing birefringent and non birefringent haemozoin area.

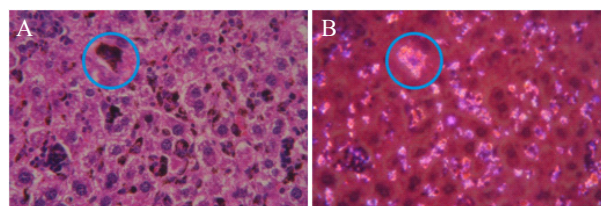


Figure 4. Haemozoin that contain Kupffer cell image in liver histology slides (A) obtained from conventional microscope (blue circle) and (B) from simple polarized microscope (blue circle).

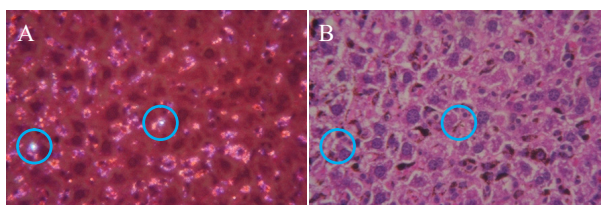


Figure 5. Image of liver histology slides obtained from (A) simple polarized microscope: dust and dirt produced a birefringence similar to haemozoin (blue circle), (B) conventional microscope: no haemozoin in this area (blue circle).

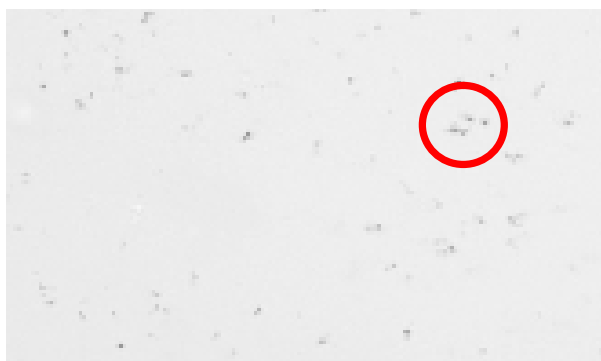

Figure 6. Haemozoin in unstained mouse liver histology (red circle) (Deroost *et al.* 2012).

DISCUSSION

A significant difference between birefringent and non birefringent haemozoin area was observed in this research. Results also showed that the average area of birefringent haemozoin measured in our images was lower than that of non birefringent haemozoin areas. This might be because in the non birefringent haemozoin images the area occupied by brown color also contained the Kupffer cells (Figure 4A), while in the haemozoin images obtained from simple polarized microscope only the haemozoin that gave a birefringence effect (Figure 4B). Haemozoin is a disposal product formed from the digestion of red blood cells by malaria parasites, and it is observed as black or brownish granules under conventional light microscope (Soniran *et al.* 2012). Therefore, it was difficult to differentiate haemozoin that attached to Kupffer cells with Kupffer cells itself due to the same brown color. Kupffer cells are macrophages cells that adhere to the endothelial lining and have variable shapes, which probably meaning that they are motile and are capable of migrating. Kupffer cells are preferentially located in the periportal sinusoids of the liver (Wisse *et al.* 1996).

In agreement with Romagosa *et al.* (2004), in this study the use of polarization microscopy in this study significantly increased the detection of malarial pigment (Romagosa *et al.* 2004). The difficulty in localizing malarial parasites also is a major problem both in blood smears (Collier & Longmore 1983) and in histological studies (Ismail *et al.* 2000). The use of polarization microscopy allows for the detection of haemozoin by scanning the slide at low magnification (200x) and is also proven to be a quick, sensitive and specific method to identify the haemozoin in placenta histology (Romagosa *et al.* 2004). Other methods that allow for the recognition of the pigment and parasites have been used in histological studies, such as modified fluorescence microscopy. Nevertheless, fluorescence microscopes are less available and more expensive than light microscopes and the technique has not been validated (Romagosa *et al.* 2004). Polarization microscopes have the additional advantage of allowing changes in contrast to be directly related to the underlying biological structure, thus enabling the determination of the structure of macromolecular complexes at a resolution of tens of nanometers (Swedlow 2012).

The sensitivity of polarized microscope for haemozoin detection in human placenta histological specimen is almost double that of conventional light microscopy (Romagosa *et al.* 2004). However, the

haemozoin detection can be false positive because dust and dirt on the slide sometimes produced a birefringence effect similar to haemozoin. This phenomenon can be avoided by checking the haemozoin area using light microscopy; as shown in Figure 5A, dust produced a birefringence similar to haemozoin. Also, in comparison with images obtained using conventional light microscope, there was no brown pigmentation in the area contaminated with dust (Figure 5B). Acid formalin as a fixative for liver histology section also can produce formalin pigment. This pigment has physical and histochemical properties similar to malarial pigment and under polarization microscopy shows as a marked birefringent similar to that of malarial pigment (Romagosa *et al.* 2004).

Another technique to measure the haemozoin area from mouse liver histology section is by using densitometry analysis in unstained mouse liver histology sections that will produced brown color haemozoin (Figure 6) (Deroost *et al.* 2012). Frita *et al.* (2012) also used non birefringent haemozoin images obtained from conventional light microscope and also used ImageJ software to measure the percentage of the liver histology section total area in the images.

We concluded that haemozoin detection in mouse liver histology can be conducted by using a simple polarized light microscope and this technique was more effective compared to conventional light microscope. Further, the use of neutral buffered formalin in place of acid formalin as a fixative will be considered in order to prevent the formation of formalin pigment that can give a birefringent effect under the polarized microscope Romagosa *et al.* (2004).

ACKNOWLEDGEMENT

The authors are greatly obliged to Mukh Syaifudin, Center for Technology of Radiation Safety and Metrology, National Nuclear Energy Agency of Indonesia for the critical reading of the manuscript. The valuable technical assistance of Devita Tetriana is gratefully acknowledged.

REFERENCES

- Baheti R, Laddha P, Gehlot RS. 2003. Liver involvement in falciparum malaria—a histo-pathological analysis. *JIACM* 4:34-38.
- Collier JA, Longmore JM. 1983. The reliability of the microscopic diagnosis of malaria in the field and in the laboratory. *Ann Trop Med Parasitol* 77:113-117.

- Deroost K, Lays N, Noppen N, Martens E, Opdenakker G, Van den Steen PE. 2012. Improved methods for haemozoin quantification in tissues yield organ- and parasite-specific information in malaria-infected mouse. *Malar J* 166:1-11.
- Egan TJ. 2003. Haemozoin (malaria pigment): a unique crystalline drug target. *Targets* 2:115-124. [http://dx.doi.org/10.1016/S1477-3627\(03\)02310-9](http://dx.doi.org/10.1016/S1477-3627(03)02310-9)
- Frita R, Carapau D, Mota MM, Hanscheid T. 2012. In Vivo hemozoin kinetics after clearance of Plasmodium berghei infection in mouse. *Malar Res Treat* 2012:1-9. <http://dx.doi.org/10.1155/2012/373086>
- Hisaeda H, Yasutomo K, Himeno K. 2005. Malaria: immune evasion by parasite. *Int J Biochem Cell Biol* 37:700-706. <http://dx.doi.org/10.1016/j.biocel.2004.10.009>
- Ismail MR, Ordi J, Menendez C, Ventura PJ, Aponte JJ, Kahigwa E, Hirt R, Cardesa A, Alonso PL. 2000. Placental pathology in malaria: an histological, immunohistochemical and quantitative study. *Human Pathol* 31:85-93. [http://dx.doi.org/10.1016/S0046-8177\(00\)80203-8](http://dx.doi.org/10.1016/S0046-8177(00)80203-8)
- Kramer B, Grobusch MP, Suttorp N, Neukammer J, Rinneberg H. 2001. Relative frequency of malaria pigment-carrying monocytes of nonimmune and semi-immune patients from flow cytometric depolarized side scatter. *Cytometry* 45:133-140. [http://dx.doi.org/10.1002/1097-0320\(20011001\)45:2<133::AID-CYTO1155>3.0.CO;2-K](http://dx.doi.org/10.1002/1097-0320(20011001)45:2<133::AID-CYTO1155>3.0.CO;2-K)
- Lawrence C, Olson JA. 1986. Birefringent hemozoin identifies malaria. *Am J Clin Pathol* 86:360-363.
- Maude RJ, Buapetch W, Silamut K. 2009. Short Report: A Simplified, Low-cost method for polarized light microscopy. *Am J Trop Med Hyg* 81:782-783. <http://dx.doi.org/10.4269/ajtmh.2009.09-0383>
- Papadopolus F, Spinelli M, Valente S, Foroni L, Orrico C, Alviano F. 2007. Common tasks in microscopic and ultrastructural image analysis using ImageJ. *Ultrastruct Pathol* 31:401-407. <http://dx.doi.org/10.1080/01913120701719189>
- Romagosa C, Menendez C, Ismail MR, Quintó L, Ferrer B, Alonso PL, Ordi J. 2004. Polarisation microscopy increases the sensitivity of hemozoin and Plasmodium detection in the histological assessment of placental malaria. *Acta Trop* 90:277-284. <http://dx.doi.org/10.1016/j.actatropica.2004.02.003>
- Silva APC, Rodrigues SCO, Merlo FA, Paixao TA, Santos RL. 2011. Acute and chronic histopathologic changes in wild type or TLR-2^{-/-}, TLR-4^{-/-}, TLR-6^{-/-}, TLR-9^{-/-}, CD14^{-/-}, and MyD-88^{-/-} mouse experimentally infected with Plasmodium chabaudi. *Braz J Vet Pathol* 4:5-12.
- Soniran OT, Idowu OA, Ajayi OL, Olubi C. 2012. Comparative study on the effects of chloroquine and artesunate on histopathological damages caused by Plasmodium berghei in four vital organs of infected albino mice. *Malar Res Treat* 2012:1-7. <http://dx.doi.org/10.1155/2012/960758>
- Sullivan AD, Meshnick SR. 1996. Haemozoin: identification and quantification. *Parasitol Today* 12:161-163. [http://dx.doi.org/10.1016/0169-4758\(96\)40001-1](http://dx.doi.org/10.1016/0169-4758(96)40001-1)
- Swedlow JR. 2012. Innovation in biological microscopy: current status and future directions. *Bioessays* 34:333-340. <http://dx.doi.org/10.1002/bies.201100168>
- Syaifudin M, Tetriana D, Darlina, Nurhayati S. 2011. The feasibility of gamma irradiation for developing malaria vaccine. *JAI* 37:91-101.
- Wisse E, Braet F, Luo D, De Zanger R, Jans D, Crabbe E, Vermoesen AN. 1996. Structure and function of sinusoidal lining cells in the liver. *Toxicol Pathol* 24:100-111. <http://dx.doi.org/10.1177/019262339602400114>

Content

HAYATI

Journal of Biosciences

Vol. 21 No. 1 March 2014

Cover photo description
A bunch of Pisang Klutuk (see article page 39)


ARTICLES

- | | | |
|------------------------------------------------------------------------------------------------------------------------------------------------------------|------------------------------------------------------------------------------|-------|
| Development of Corn Milk Yoghurt Using Mixed Culture of <i>Lactobacillus delbruekii</i> , <i>Streptococcus salivarius</i> , and <i>Lactobacillus casei</i> | Sedarnawati Yasni, Ayuni Maulidya | 1-7 |
| Dietary Variation of Long Tailed Macaques (<i>Macaca fascicularis</i>) in Telaga Warna, Bogor, West Java | Sarah Nila, Bambang Suryobroto, Kanthi Arum Widayati | 8-14 |
| Identification of New Lactone Derivatives Isolated from <i>Trichoderma</i> sp., An Endophytic Fungus of Brotowali (<i>Tinaspora crispa</i>) | Elfita, Munawar, Muharni, Mastur Adhy Sudrajat | 15-20 |
| Independent Effects of Temperature, Salinity, Ammonium Concentration and pH on Nitrification Rate of the Ariake Seawater Above Mud Sediment | Alim Isnansetyo, Sai Getsu, Masahiro Seguchi, Masumi Koriyama | 21-30 |
| Field Adaptation of Some Introduced Wheat (<i>Triticum aestivum</i> L.) Genotypes in Two Altitudes of Tropical Agro-Ecosystem Environment of Indonesia | Adeel Abdul Karim Altuhaish, Miftahudin, Trikoesoemaningtyas, Sudirman Yahya | 31-38 |
| Genetic Diversity of <i>Musa balbisiana</i> Colla in Indonesia Based on AFLP Marker | Fajarudin Ahmad, Rita Megia, Yuyu Suryasari Poerba | 39-47 |

SHORT COMMUNICATION

- | | | |
|--------------------------------------------------------------------------------------|---------------------------------------------|-------|
| Haemozoin Detection in Mouse Liver Histology Using Simple Polarized Light Microscope | Dwi Ramadhani, Siti Nurhayati, Tur Rahardjo | 48-52 |
|--------------------------------------------------------------------------------------|---------------------------------------------|-------|

Listed in:



www.crossref.org/

DOAJ DIRECTORY OF
OPEN ACCESS
JOURNALS
www.doaj.org/



www.ebscohost.com

ProQuest
Start here.



www.cabi.org



Published four times in a year