

Original Article

The black rice ethanol extract effect on polymorphonuclear cells proliferation of rats induced by lipopolysaccharide

Henny Juliastuti^{1*}, Maman Djamaludin², and Hadi Alwani³

- 1) Department of Biochemistry Faculty of Medicine, Universitas Jenderal Achmad Yani
- 2) Department of Pharmacology Faculty of Medicine, Universitas Jenderal Achmad Yani
- 3) Bachelor of Medicine Study Program, Faculty of Medicine, Universitas Jenderal Achmad Yani

*Email corresponding author : juliastuti.henny@gmail.com

ABSTRACT

Inflammation is a defense that exists in the body when an infection occurs. Excessive inflammatory reactions can be induced by lipopolysaccharides (LPS) which are the most immunogenic components of a bacterial capsule or cell wall, which will result in damaging effects on the body. Black rice (*Oryza sativa L.indica*) is one of the natural ingredients that contains phenols, flavonoids, and antioxidant anthocyanin as immunomodulator. This study aims to find out the effect of giving black rice ethanol extract as an anti-inflammatory to the proliferation of polymorphonuclear cells (PMN) in the spleen of rats induced on lipopolysaccharides. This study was conducted using 27 mice who were given black rice ethanol extract as much as 400 mg/kg BW in 14 days and then rats induced by LPS 0.3 mg/kg BW at 24 hours intraperitoneally before being CO₂ euthanized and taken the spleen to be checked for measuring the size of the germinal center diameter. The observations showed the results of the germinal center diameter size in the treatment group with a value of $1,311 \pm 0,226 \mu\text{m}$ ($p < 0,05$ compared to positive control group which showed that LPS administration led to the disorganization of the white pulp and the reduction of lymphocyte cells and PMN in the germinal center. In conclusion, black rice ethanol extract at a dose of 400 mg/kgBB can affect the proliferation of PMN indicated by changes in the morphology of the white pulp in the germinal center in the spleen of rats.

Keyword: anthocyanin, black rice, Inflammatory, lipopolysaccharides, PMN proliferation,

INTRODUCTION

The body creates inflammation in response to infections, which can lead to damage if excessive amount are produced. Lipopolysaccharides (LPS) are the most immunogenic compound found in bacteria's capsules and cell walls, and as such can cause excessive inflammatory responses.¹⁻⁴ Inflammation occurs in response to protect the body from an infection, but if an excessive inflammatory reaction will occur an impact that can damage and harm the body, so the inflammatory process must be adequate but should not be excessive so that tissue damage does not occur. To overcome this requires an anti-inflammatory drug in order to control the inflammatory reaction so as not to cause harm to the body. Anti-inflammatories are agents or drugs that work to suppress inflammatory processes. Along with the need for anti-inflammatory and increased understanding of *back to nature*, it was studied foodstuffs that contain phenols, flavonoids, antioxidant anthocyanin as a high immunomodulator, one of which is black rice (*Oryza sativa L.indica*). Black rice has a high content of antioxidants and immunomodulators compared to other types of rice, so a lot of research and research is done using black rice for drug development material.⁵⁻⁷

The use of black rice ethanol extract as an anti-inflammatory in Hartati's study showed the highest anti-inflammatory activity result was a dose of 100 mg/kg BW. Based on research from Liu H, Huang and Pei X, said black rice ethanol extract has an effective anti-inflammatory at doses of 200 and 400 mg/kg BW.⁸⁻⁹ In previous studies have not been explained further about the direct influence of black rice administration on organs related to the process of PMN cells proliferation in the spleen, so in this study used a dose of 400 mg/kg BW black rice ethanol extract against proliferation. The target organ studied in this study was the spleen because it is an organ that eliminates antigens and an innate and adaptive

immune response to pathogens. PMN in the spleen. The target organ that studied in this study is the spleen, when an infection occurs, spleen is an organ that will remove antigens carried by the blood and also initiates an immune response and adaptive to pathogens. The spleen also places zones containing T and B cells as a place for the formation of antigen-specific immune responses to protect the body against bacteria that come from blood.¹⁰

The content of active substances contained in black rice can be used as an anti-inflammatory and antioxidant because it can reduce cell damage caused by free radicals formed during inflammation, so the author wants to know the effect of giving black rice ethanol extract as an anti-inflammatory against the proliferation of PMN in the spleen of white rats induced lipopolysaccharides.¹¹⁻¹³

METHODS AND SUBJECT

The study subjects used 27 wistar strain male rats from Biofarma. Animals tried to be adapted in the Animal Laboratory of Faculty of medicine Universitas Jenderal Achmad Yani for 7 days. At the time of the study, the rats were divided into three groups, namely the positive control group, negative control, and the treatment group. Objects used black rice ethanol extract derived from the *Oryza sativa L. Indica*. The ingredients used for the study were black rice ethanol extract at a dose of 400 mg/kg BW, rat pellet food and drinking water, alcohol 70%, CO₂ gas, 10% formalin, CMC 1%, PMN cells from spleen, object glass, cover glass, Hematosilin-Eosin dye.

Rats were acclimatized for seven days as to see if the condition of the rats matched the criteria of the study. Then after acclimatization, the treated rats were given black rice ethanol extract 400 mg /kg BW for 14 days. The extract was given 1 time a day in the morning [15]. On the 22nd day of LPS induction it aims to find out the effect of black rice ethanol extract on the physiological functions of the body and the

behavior of experimental animals and on the 23rd day it is eliminated for sampling the spleen of rats. In group 1 as a negative control given only 25-35g/head feed, drinking aquadest. Group 2 as a positive control given feed 25-35g /head, drinking aquadest then induced LPS 0.3 mg / kg BW intraperitoneally. Group 3 as a treatment 3 is given feed 25-35g / head, drink aquadest, given black rice ethanol extract as much as 400 mg / kgBB then induced LPS 0.3 mg / kgBB intraperitoneal.⁸⁻⁹

The preparation used is lipopolysaccharide (LPS) from *Salmonella typhi*. LPS is made by dissolving LPS in phosphate buffered saline. On the 15th day, the animals tried in the positive control group (K2), the treatment group 3 (P3) was injected intraperitoneally with LPS 0.3 mg /kg BW. The purpose of LPS administration was to induce an inflammatory state in mice.¹⁴ Rats were treated 24 hours before CO₂ euthanasia. In the process of inflammation of the early phase, the first 24 hours of cells that react neutrophil or polymorphonuclear leukocytes.¹⁵

After the completion of the 'preparat', then followed by histopathological observations carried out under a confocal microscope (Olympus BX41) with

magnification of 100x and 400x to assess germinal center in the spleen. The reading of the preparation is carried out by the Micely scoring method. A score of 1 indicates a well-organized spleen that has a different periarteriolar lymphocyte sheath, lymphoid follicles and marginal zones, with a varying number of secondary lymphoid follicles, containing a germinal center that is clearly bounded by the edges of small lymphocytes (mantle zone). A slightly irregular score of 2 has hyperplastic or hypoplastic changes that blur the boundaries between white pulp regions. A score of 3 occurs moderate to extensive disorganization in the white pulp area, not well individualized or lymphoid follicles are unclear.¹⁶

RESULTS AND DISCUSSION

Results of Histopatologis Germinal center

Histopatologis preparations are taken from the spleen of white rats of the male wistar strain from the *omentum* area by giving *haematoxylin eosin* (HE) coloring to color the *spleen germinal center*. Qualitative observations were made with the aim of seeing the size of the diameter of the *germinal center* of the white rat wistar strain

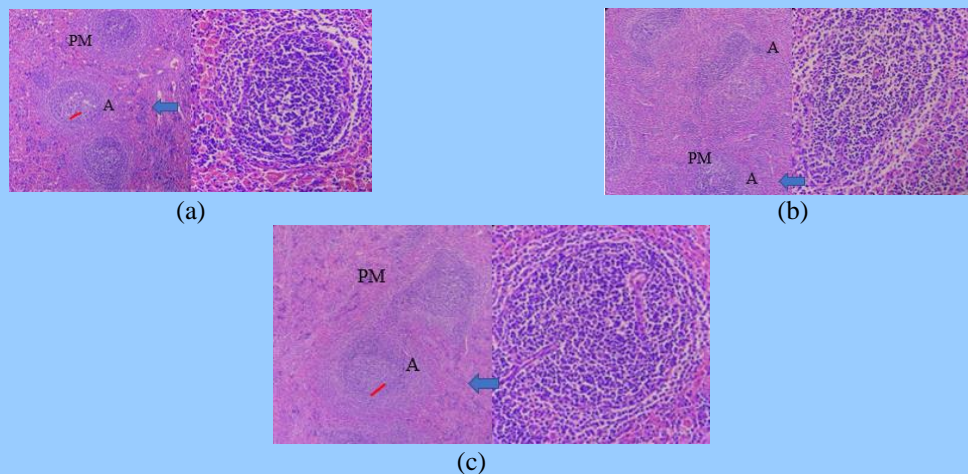


Figure 1 Overview of lymph histology with Hematoxylin Eosin coloring. Left image of 100x magnification and right image of 400x magnification

Description: (a) negative control (b) positive control (c) Treatment Group; white pulp (blue arrow); red pulp (pm) germinal center (a); mantle zone (red line)

The results of histopathological observations were carried out at objective magnification of 100x and 400x. The results of histopathological observations of the treatment group began to be clearly seen again clearly the clear area of the white pulp and red pulp. In the white pulp there is a boundary between the mantle zone and the *germinal center*. *Germinal* centres appear to have a high density that is more or less the same as the negative control group. While in positive control looks a slightly difficult area to observe in distinguishing white pulp and red pulp, where this occurs due to disintegration in the white pulp. . The boundaries of the

mantle zone on the white pulp have begun to decrease or disappear with *the germinal center*. *Germinal center* looks at the arrangement of cells that begin to stretch, where this is due to the provision of LPS. Inflammatory proses affect the germinal center so that there is a widening of the diameter, in contrast to normal and dossing.

Results of Histopatologis White Pulp Quantitatively

The data that has been collected then done statistical calculations can be seen in table 1 diameter *germinal center* spleen white pulp between groups (units μm).

Table 1 Germinal Diameter center of intergroup white pulp (Unit μm)

Group	Mean (μm) \pm SD	Minimum	Maximum
Negative control group	1,133 \pm 0.173	1,00	1,40
Positive control group	1,956 \pm 0.089	1,80	2,00
Treatment group	1,311 \pm 0.226	1,00	1,60

In table 1 the average value of the white pulp of germinal center diameter showed the positive control group had the highest value of 1.956 \pm 0.089, followed by the treatment group with a value of 1.311 \pm 0.226 while the negative control group showed the smallest average value with a

value of 0.133 \pm 0.173 . This suggests that a dose of 400 mg / kg BW has the ability to stimulate the formation of a cellular immune response in the form of an anti-inflammatory response characterized by the docking of the size of the diameter of the white pulp germinal center.

Table 2 Mann Whitney Test Results

Group	Value p*	Interpretation
Negative control - positive control	0,000	There is a difference
Positive control – treatment 3	0,000	There is a difference
Negative control- treatment 3	0,113	There is no difference

The availability:
*p \leq 0.5 (there are significant differences)

The results of the analysis in Table 2 showed that there was a significant difference in germinal center diameter between the negative control group and the positive control group, between the positive control group and treatment group, but there was no meaningful difference in germinal center diameter between the negative control group and the treatment group.

The results of the analysis showed that LPS administration led to the organization of white pulp and reduced lymphocyte cells and PMN in the germinal center. Giving black rice ethanol extract at treatment group can affect cell density in the germinal center area in the spleen and changes in the morphology of the white pulp as an anti-inflammatory effect of flavonoid compounds contained in it. This is likely to occur due to 2 things, where the proliferation of PMN cells in the bone marrow is faster so that there is no reduction of cells in the spleen germinal center, or the migration of PMN from the spleen to the tissues is not as massive as in K2. The diameter of the germinal center in the group before LPS administration was no different from negative control, indicating that ethanol extract administration had chemopreventive therapeutic effects. This happens because flavonoids can bind directly to kinase protein suppression. Protein kinase is involved in signal transduction when inflammation occurs.¹²⁻¹⁶ This shows that the administration of black rice extract is able to guard against damage due to LPS administration.

Flavonoids are compounds of phenyl compounds substituted derivate benzopyran consisting of the basic skeleton C15 (C6-C3-C6). Some plants contain flavonoid derivatives have been used as disease prevention and therapeutic agents in traditional medicine in Asia for thousands of years, including immunomodulators.¹⁷⁻²² The presence of flavonoids, saponins, tannins, glycosides in ethanol and ethylacetate extracts suggests that the extract has anti-inflammatory and immunomodulatory effects.²³⁻²⁶

Anthocyanin compounds are believed to be used as immunomodulator referring to Hartati's research on the antioxidant activity and immunomodulator of black rice (*Oryza sativa L.indica*). Anthocyanins in addition to contained in black rice can also be found in plants and fruits that are dark in color such as brown rice and black wine. Research that mentions that anthocyanin contained in black rice can improve spleen function, so this basis can be used as one of the clues that increase the number of cells. In the spleen, especially the germinal center area, the level of neatness increased when compared to the positive control group.²⁶

CONCLUSION

Based on the results of this study, it can be concluded that the ethanol extract of black rice can affect the proliferation of PMN indicated by changes in the morphology of the white pulp in the *germinal center* area in the spleen of rats induced by LPS.

ACKNOWLEDGEMENTS

The author grateful for the insightful comments offered by the anonymous peer reviewers at journal.

DECLARATION OF INTERESTS

There is no conflict of interest in the scientific articles written.

FUNDING

This work would not have been possible without the financial support of the Lembaga Penelitian dan Pengabdian Masyarakat (LPPM) Universitas Jenderal Achmad Yani.

REFERENCES

1. Wahyuningsih P, UP Nursing. Effect of Tintir Distance Extract (*Jathropa Multifida*, Linn) on the Amount of PMN and Mast Selt on Rat Wound Healing with Acute Need Model. *Journal homepage*. 2019;4(1):p1-6.
2. Harlim A. Textbook on Skin Health Science and Genital IMMUNOLOGY

- INFLAMMATORY. 1 2008. FK UKI; p1386.
3. VK's sgiaman. Improved Wound Healing in the Oral Mucosa Through The Administration of Aloe Vera (Linn.) Topically Topically. Maranatha Journal of Medicine and Health. 2011;11(1):p70-79.
 4. Hannoodee S, Dn N. Acute Inflammatory Response Issues of Concern Clinicopathologic Correlations. acute inflammatory response. Published online 2021:p7-10.
 5. FK treasure. Evaluation of Phytochemicals, Antioxidant Activity and Immunomodulators of Black Rice (*Oryza Sativa L. Indica*). 2016.
 6. Wijayanti CRT. Anti-Inflammatory Power of Ethanolic Extract *Tripterygium Root wilfordii* Hook. F. on the female White squeak. Thesis of Sanata Dharma University. Published online 2008:p12-13.
 7. Alviyani E. Test the Antioxidant Activity of White Rice Ethanol Extract and Black Rice Using the DPPH Method in Gel Form. Thesis. Published online 2020:p1-120.
 8. FK treasure. Anti-inflammatory Activity of Ethanol Extract And Black Rice Water (*Oryza sativa L. indica*) In Male Wistar Rats. Journal of Recapangan. 2016;10(1):p9-15.
 9. Liu H, Huang L, Pei X. Effects of sorghum rice and black rice on genes associated with cholesterol metabolism in hypercholesterolemic mice liver and intestine. Food Science and Nutrition. 2021;9(1):p217-29.
 10. Bronte V, Pittet MJ. The spleen in local and systemic regulation of immunity. Immunity. 2013;39(5):p806-18.
 11. Noor Mutsaqof AA, - W, Suryani E. Expert System For Diagnosing Infectious Diseases Using Forward Chaining. ITSmart Journal of Technology & Information. 2016;4(1):p43.
 12. Abidin Z. Effects of Ethanol Extract *Oryza sativa L. indica* on Kinase B Protein Activity and SERUM CA 15-3 Levels in Female Dawley Sprague Mice. eJournal Medis Indonesia Journal Medis Indonesia. 2017;4(3):p187-90.
 13. Mangiri J, Mayulu N, Kawengian SES. An overview of the nutritional content in black rice cultivar Pare Ambon South Sulawesi. Journal of e-Biomedicine. 2016;4(1):p2-6.
 14. Khan A, Tahir A, SU R, et al. Neuroprotective Effect of Quercetin Against the Detrimental Effects of LPS in the Adult Mouse Brain. Frontiers in Pharmacology. 2018;9:p1-59.
 15. Muhammad Nizar. Probiotic Administration Of Gingiva Lymphocyte Cells Count of Wistar Rats Induced Lipopolysaccharides. Jember: Faculty of Dentistry, University of Jember. 2012.
 16. Hermida M d. ER, de Melo CVB, Lima I dos S, Oliveira GG de S, dos-Santos WLC. Histological Disorganization of Spleen Compartments and Severe Visceral Leishmaniasis. Frontiers in Cellular and Infection Microbiology. 2018;8.
doi:10.3389/fcimb.2018.00394
 17. Maleki SJ, Crespo JF, Cabanillas B. Anti-inflammatory effects of flavonoids. Food Chemistry. 2019;299(July).
 18. Istanti NW, Nabila RA, Listyawati S. Nutritional content of black rice (*oryza sativa l.*) is the result of breeding plants with gamma rays of 60 co. Proceedings of Meetings And Scientific Presentations of Basic Research on Nuclear Science and Technology. Published online 2018:p295-8.
 19. Maharni M. Potential White rice, black rice and brown rice as antioxidants and inhibitors of thyrosinase. Thesis of Bogor Agricultural University. Published online 2015:p1-31.
 20. Zahroh F, Agustini R. Determination of the total anthocyanin content of black rice yeast using the differential pH method. Journal of Chemistry of Neger

- University Surabaya. 2021;10(2): p200-8.
21. Arifa AH, Shamsir E, Budijanto S. Physicochemical Characterization of Black Rice (*Oryza sativa* L.) from West Java, Indonesia. *agriTECH*. 2021;41(1):p15. doi:10.22146/agritech.53307
 22. Durga M, Nathiya S, Devasena T. Immunomodulatory and antioxidant actions of dietary flavonoids. *International Journal of Pharmacy and Pharmaceutical Sciences*. 2014;6(2):p5056.
 23. Tungmunnithum D, Thongboonyou A, Pholboon A, Yangsabai A. Flavonoids and Other Phenolic Compounds from Medicinal Plants for Pharmaceutical and Medical Aspects: An Overview. *Medicines*. 2018;5(3):p93.
 24. Yu GJ, Choi IW, Kim GY, Kim BW, Park C, Hong SH. Anti-inflammatory potential of saponins derived from cultured wild ginseng roots in lipopolysaccharide-stimulated RAW 264.7 macrophages. *International journal of molecular medicine*. 2015;35(6):p1690-8.
 25. Ahn S, Siddiqi MH, Noh HY, Kim YJ, Jin CG, Yang DC. Anti-inflammatory activity of ginsenosides in LPS-stimulated RAW 264.7 cells. *Science bulletin*. 2015;60(8):p773-84.
 26. Yang M, Koo S, Song W, Chun O. Food Matrix Affecting Anthocyanin Bioavailability: Review. *Current Medicinal Chemistry*. 2011;18:p291-300.