

Case Report

Management of Bilateral Sudden Deafness

Yunita Wulandari 1), Jacky Munilson 2)

1) PPDS Bagian THT-KL Fakultas Kedokteran Universitas Andalas, 2) Bagian THT-KL Fakultas Kedokteran Universitas Andalas/RSUP Dr.M.Djamil Padang

ABSTRACT

Introduction: Sudden deafness or sudden sensorineural hearing loss (SSNHL) is defined as sensorineural hearing loss of more than 30 dB at three consecutive frequencies within 3 days of onset, often unilateral, and only 0,4-3,4 % of patients with bilateral of sudden deafness. The definite cause of sudden deafness is only found in 10-15% cases and most of the cause was unknown (idiopathic). The management of systemic corticosteroid injection is the first choice in the treatment of SSNHL and can be combined with corticosteroid intratympanic injection. **Case reported:** A 33-year-old male patient with diagnosis of bilateral sudden deafness which is performed systemic corticosteroids and combined with dexamethasone injection intratympanic with the good result. **Conclusion:** the combination therapy of intratympanic corticosteroids and systemic corticosteroids has been reported to have advantages over systemic corticosteroid therapy alone. Several studies have shown good results using intratympanic steroids in cases of sudden deafness, both as primary therapy and as adjuvant therapy (combination).

Keywords: Sudden deafness, sensorineural hearing loss, intratympanic injection

ABSTRAK

Pendahuluan: Tuli mendadak didefinisikan sebagai kehilangan pendengaran sensorineural yang lebih dari 30 dB pada 3 frekuensi berturut-turut dalam onset 3 hari, sering unilateral, hanya sekitar 0,4-3,4% dari pasien yang mengalami tuli mendadak bilateral. Penyebab pasti tuli mendadak hanya ditemukan pada 10-15% kasus, sebagian besar penyebabnya tidak diketahui (idiopatik). Tatalaksana injeksi kortikosteroid sistemik menjadi pilihan utama pada tatalaksana tuli mendadak dan dapat dikombinasikan dengan kortikosteroid injeksi intratimpani. **Laporan Kasus:** satu kasus pasien laki-laki, 33 tahun yang didiagnosis dengan tuli mendadak bilateral yang dilakukan terapi kortikosteroid sistemik dan dikombinasikan dengan injeksi deksametason intratimpani dengan hasil yang baik. **Kesimpulan:** terapi kombinasi kortikosteroid intratimpani dan kortikosteroid sistemik telah dilaporkan memiliki keunggulan dibandingkan terapi kortikosteroid sistemik saja. Beberapa penelitian menunjukkan hasil yang baik dalam penggunaan steroid intratimpani pada kasus tuli mendadak, baik sebagai terapi primer maupun sebagai terapi adjuvant (kombinasi).

Kata Kunci: Tuli mendadak, tuli sensorineural, injeksi intratimpani

Korespondensi

Yunita Wulandari, PPDS Bagian THT-KL Fakultas Kedokteran Universitas Andalas/ RSUP DR. M. Djamil Padang, wulannwulann@gmail.com, 081287833356

INTRODUCTION

Sudden deafness is sensorineural deafness of 30 dB or more at three consecutive frequencies and occurs within three days.^{1,2}

Based on the etiology, sudden deafness is divided into two categories, namely sudden deafness with clear causes (infection, neoplasm, trauma, ototoxic, immunological, vascular and psychogenic) and idiopathic sudden deafness.²⁻⁴

On physical examination, patients almost always have normal results. Audiometric examination is needed to prove deafness and determine the degree of hearing loss. Bone conduction and air

conduction in pure tone audiometry help determine the type of deafness, whether conductive deafness, sensorineural deafness, or mixed deafness. Tympanometry and acoustic reflex examinations can also distinguish conductive hearing loss from sensorineural hearing loss and provide additional clues to etiology. A complete laboratory examination is performed to assess markers of inflammation, including C-reactive protein. Laboratory results also show the presence of systemic diseases such as diabetes, hyperlipidemia and autoimmunity.^{2,5}

Sudden deafness therapy consists of: anti-inflammatory (oral, systemic and intratympanic injection corticosteroids), vasodilators, rheologic agents, antivirals, diuretics, triiodobenzoic acid derivatives, hyperbaric oxygen, carbogen inhalation, and surgery.^{1,2,4}

There are 3 protocols for the use of intratympanic steroids in cases of sudden deafness, namely: primary therapy, adjuvant therapy, and salvage therapy.⁶

There are several parameters used to assess hearing improvement in sudden hearing loss, including Siegel's criteria; (1) complete recovery: final hearing threshold <25 dB, (2) partial recovery: hearing improvement >15 dB and final hearing threshold 25 until 45 dB, (3) slight improvement: hearing improvement >15 dB and final hearing threshold >45 dB, (4) no improvement: hearing improvement <15 dB and final hearing threshold >75 dB.⁷

The aim of this case report is to determine the success of combination of systemic corticosteroid therapy and intratympanic corticosteroid in bilateral sudden deafness patients.

CASE REPORT

It was reported a man, 33 years old, came to the ORL-HNS outpatient clinic of Dr. M. Djamil Padang on August 5th, 2019, complaining of a sudden decrease in hearing in the right ear since 4 days before admission, this complaint was felt suddenly when the patient woke up. Initially, a week ago, complaints of hearing loss were also complained of in the patient's left ear which occurred suddenly when the patient woke up. The complaint was accompanied tinnitus in both ears, especially in the right ear since a week ago. There was no previous history of watery ears and ear pain, no history of head and ear trauma, no history of exposure to noise. There was no history of dizziness. There were no history of fever, cough and cold. There was no history of severe headache. There were no history of diabetes, and hypertension. There was no history of long-term drug use. There was no history of rash on the face and history of muscle pain. The patient works as a farmer.

Physical examination within normal limits. The tuning fork

examination with the result bilateral sensorineural deafness. A simple balance test is obtained within normal limits. Facial nerve examination did not reveal facial nerve paresis. On pure tone audiometry examination, it was found that the right ear was very severe sensorineural deafness with a hearing threshold of 93.75 dB, the left ear was found very severe sensorineural hearing loss (profound) with a hearing threshold of 116.25 dB (Figure 1). Complete blood laboratory examination results showed total cholesterol 220 mg/dl, negative ASTO, negative Rheumatoid Factor. The result was hypercholesterolemia, other results within normal limits.

The patient was diagnosed with bilateral sudden hearing loss. The patient was treated and planned for systemic corticosteroid administration. Patients were given oxygen inhalation therapy 4 liters/minute for 15 minutes every 6 hours, injection of methylprednisolone 1x500 mg tapering off, vitamin B complex tablets 3x1, folic acid tablets 1x1, low-salt and low-fat diet and bed rest.

On August 8th, 2019 (third day of treatment) the patient is planned to be given an intratympanic injection. Intratympanic

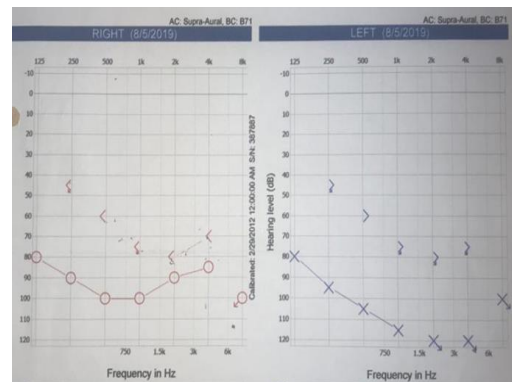


Figure 1. Audiogram before injection

injection of dexamethasone is planned to be done 4 times. The first intratympanic injection was carried out on the third day of treatment and the following injection procedure was carried out: previously dexamethasone 5 mg (ampoule) was immersed in warm water until it was according to body temperature (37°C). The patient sleeps on his back with his head rotated about 45° to the right, the left ear is

cleaned, then aseptic and antiseptic is done using betadine, then local anesthesia is carried out using a xylocain spray which is sprayed on a cotton roll then inserted into the ear canal to the tympanic membrane, left for 10 minutes then cotton raised. Dexamethasone 5 mg/ml is injected as much as 0.8 ml into the tympanic cavity through the posteroinferior quadrant of the tympanic membrane using a 1 ml syringe with a needle no. 23G. The tip of the syringe is bent, with a dexamentasone microscope guide injected. After injection, the patient's position is maintained for 30 minutes. Furthermore, the same procedure was performed for the right ear. After the injection is complete, evaluate the patient's post-injection response for dizziness, nausea or vomiting. In this patient there are no complaints. After intratympanic injection, the patient is advised to sleep as comfortably as possible, using a pillow.

After the injection, the patient was again treated to continue giving oxygen inhalation of 4 liters/minute for 15 minutes every 6 hours of injection of Methylprednisolone tapering off, vitamin B complex tablets 3x1, folic acid tablets 1x1. Intratympanic injection was carried out every week 4 times in a row.

On September 3rd, 2019, 1 week after the fourth intratympanic injection, patient went to the ORL-HNS outpatient clinic, the patient had no complaints and the patient said that there was an improvement in his hearing.

An audiometric examination was performed and it was found that the right ear had severe sensorineural deafness with a hearing threshold of 77.5 dB, the left ear had very severe sensorineural hearing loss with a hearing threshold of 103.75 dB. (Figure 2). The patient is then advised to use a hearing aid.

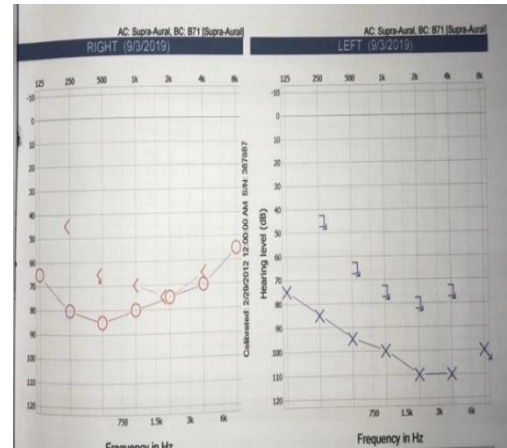


Figure 2. one week after the fourth intratympanic injection

On October 10th, 2019, a month after the intratympanic injection, patient went to the ORL-HNS outpatient clinic, Dr. M. Djamil Padang, the patient complained of a decrease in hearing loss, no ringing in the ears, no dizziness. The patient had been advised to insert a hearing aid after the fourth intratympanic injection, two months ago, but the patient refused.

Performed an audiometry examination, it was found that the right ear had severe sensorineural deafness with a hearing threshold of 71.25 dB, the left ear had very severe sensorineural deafness with a hearing threshold of 97.5 dB (Figure 3). The patient is then advised to install hearing aids.

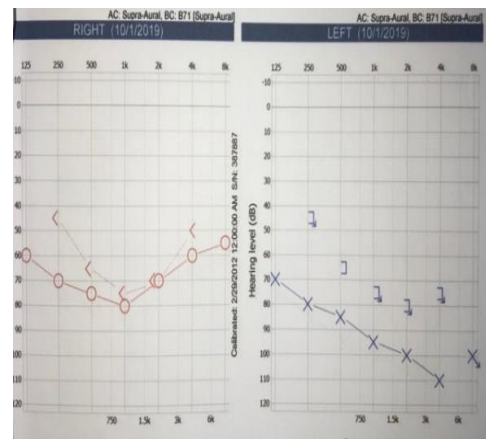


Figure 3. a month after the intratympanic injection

DISCUSSION

A 33 years old male patient with sudden bilateral deafness was reported. Several large-scale case studies conducted

in the United States, Europe and Japan show that sudden deafness occurs between the ages of 43-53 years.⁴ Equal sex distribution between men and women.^{3,8} Zhang⁸ in China found 282 cases of sudden deafness in the left ear, 267 cases in the right ear and 68 cases in both ears. In the history, the main complaint in this case was a sudden decrease in hearing in the right ear since 4 days before admission to the hospital and the left ear since 7 days before admission to the hospital.

As described in some literature sudden deafness is a sensorineural hearing loss that occurs more than 30 dB at 3 or more frequencies consecutively with an onset of less than 3 days.^{9,10} Accompanied by complaints of ringing in the ears (tinnitus).

The patient complained of ringing in the right ear. This is consistent with the literature which states that tinnitus is a comorbid symptom in most cases of sudden deafness.

Meanwhile, vestibular symptoms appear in one quarter to half of cases.² Zhang⁸ in China, 87.2% of 617 patients reported sudden deafness as complaining of tinnitus, whereas dizziness or vertigo was reported in 48.5% of patients. Tong⁵ in China got tinnitus as accompanying symptom of sudden deafness in 88.3% of 418 patients, 64.5% of whom were low pitch.

In this patient, a laboratory examination was performed and the impression was hypercholesterolemia. Hypercholesterolemia is one of the significant predisposing factors for sudden deafness.¹¹ Tong¹² found that hypertension, coronary disease and diabetes were found in 19.6% of 418 cases of sudden deafness and 54.5% of hyperlipidemia cases.

Although many epidemiological studies have been conducted, the pathological mechanism of sudden deafness is still not known with certainty.⁸ Approximately 85% of cases are idiopathic.¹³ Viral infections are usually associated with patients under 50 years of age, whereas vascular disorders are in patients over 50 years.¹⁴

Diagnosis of sudden deafness is based on history taking physical examination, audiometry, and laboratory

examination. History leading to onset, time span, other symptoms associated with tinnitus or vertigo, past medical history including risk factors and history of drug use, especially those of an ototoxic medication.

In this case, management was carried out with primary therapy, namely systemic corticosteroid therapy as the first treatment for sudden deafness and combined with intratympanic injection according to the procedure in the ORL-HNS Dr. M. Djamil Padang. Lee's study¹⁵ concluded that combination therapy of intratympanic injection with systemic corticosteroids is superior to systemic corticosteroids alone. The use of intratympanic steroids as primary therapy without systemic steroids was initially used in patients who could not use systemic steroids, such as patients with hypertension and uncontrolled diabetes mellitus.^{16,17}

Kara¹⁸ stated in his study that intratympanic steroid injection provided better hearing results than systemic steroids. Hong¹⁹ in his study stated that there was an improvement in hearing given intratympanic injection compared to oral steroids. Hamid²⁰ in his research showed dexamethasone to be more effective than methylprednisolone. This is because the absorption of dexamethasone into the striae and surrounding tissues is faster than methylprednisolone which lasts longer in the endolymph for about 4-6 hours. Steroids act intracellularly on the striae and surrounding tissue after active or passive endocytosis. High levels of methylprednisolone in endolymph show an inverse association with its intracellular effectiveness, so that dexamethasone is more effective for intratympani perfusion.

In this patient, the hearing threshold after being diagnosed with bilateral sudden deafness had an impression in the right ear, very severe of sensorineural deafness with a hearing threshold of 93.75 dB, in the left ear, very severe with a hearing threshold of 116.25 dB (profound). And after injection therapy of systemic corticosteroids combined with intratympanic injection of hearing threshold, the right ear was seen with severe sensorineural hearing loss with a hearing threshold of 71.25 dB, in the left

ear, there was very severe sensorineural hearing loss with a threshold of 97.5 dB.

Research by Ferri et al²¹ cited by Khot in his study on 16 patients (29.1%) with hearing loss more than 90 dB experienced an average improvement of 7.2%, 29 patients (52.7%) with impaired hearing less than 50-90 dB experienced an average improvement of 21.2%, 10 patients (18.2%) with a hearing loss of 30-50 dB experienced an average improvement of 47.6%.²¹ In this case, from audiometric examination, there was an improvement of 22.5 dB for the right ear and 18.75 dB for the left ear.

The audiometry results after systemic corticosteroid injection and 4 intratympanic injections showed a significant increase in hearing threshold. According to Siegel's criteria, this patient is included in the criteria, slight improvement namely hearing improvement >15 dB and the final hearing threshold >45 dB and the patient is recommended to use hearing aids.

In conclusion, the combination therapy of intratympanic corticosteroids and systemic corticosteroids has been reported to have advantages over systemic corticosteroid therapy alone. Several studies have shown good results using intratympanic steroids in cases of sudden deafness, both as primary therapy and as adjuvant therapy (combination).

REFERENCES

1. Dhingra PL, Dhingra S. Hearing Loss. Disease of Ear, Nose and Throat & Head and Neck Surgery. Sixth Edition. Haryana: Replica Press; 2014:29-40.
2. Oliver ER, Hashisaki GT. Sudden sensorineural hearing loss. In: Johnson JT, Rosen CA, editor. Bailey's Head & Neck Surgery. Otolaryngology. Fifth Edition. Philadelphia: Lippincott Williams & Wilkins; 2014:2589-96.
3. Arts HA. Sudden Sensorineural Hearing loss in Adults. In: Flint PW, Haughey BH, Lund VJ, Niparko JK, Richardson MA, Robbins KT, editor. Cummings Otolaryngology Head & Neck Surgery. Sixth edition. Philadelphia: Elsevier; 2015: 2319-35.
4. Goldenberg D, Goldstein BJ. Otologic Emergencies. In: Handbook of Otolaryngology. New York; Thieme. 2011:102-4.
5. Selvadurai DK. Sensorineural Hearing Loss. In : Husein SM, editor. Logan Turner's. Disease of The Nose, Throat and Ear. Head and Neck Surgery. Eleventh Edition. Boca Raton : Taylor & Francis Group LLC : 2016: 443-51
6. Seok I, Jin M, Lee KS, Seung H. How long should the sudden hearing loss patients be followed after early steroid combination therapy ? 2009;(123):1391-5
7. Inoue DP, Bogaz EA, Barros F, Penido NDO. Comparison of hearing recovery criteria in sudden sensorineural hearing loss. Braz J Otorhinolaryngol. 2012;78(3):42-48.
8. Zhang X, Xu X, Ma W, Zhang Q, Tong B, Yu H, et al. A clinical study of sudden deafness. Acta Otolaryngologica. 2015;1-6.
9. Stachler RJ, Chandrasekhar SS, Archer SM, et al. Clinical practice guideline: Sudden hearing loss. Otolaryngol - Head Neck Surg. 2012;146
10. Lazarini PR, Camargo ACK. Idiopathic sudden sensorineural hearing loss: Etiopathogenic aspects. Braz J Otorhinolaryngol. 2006;72(4):554-61.
11. Aimoni C, Bianchini C, Borin M, Ciorba A, Fellin R, Martini A, et.al. Diabetes, Cardiovascular Risk Factors and Idiopathic Sudden Sensorineural Hearing Loss: A Case-Control Study. Audiol Neurotol. 2010;15:111-15
12. Tong ZX, Bin S, Juan ZW, Min X, Rong WJ. Concurrent symptoms and disease conditions in sudden deafness. J Otol. 2010;5(1):20-23
13. Weber PC and KS. Anatomy and Physiology of Hearing. In : Bailey's Head and Neck Surgery Otolaryngology. 5th ed. Williams Lippincott & Wilkins ; 2014:2253-73.
14. Gonzales MAL, Abrante A, Lorente CL, Dominguez E, Antonio G, Esteban F. Acute- Phase Inflammatory Response in idiopathic

- Sudden Deafness: Pathogenic Implications. *International Journal of Otolaryngology*. 2012;1-5.
15. Lee KJ. Non Infectious Disorder of the Ear. *Essential Otolaryngology. Head and Neck Surgery*. Eleventh Edition. New York; Boca Raton; 2016;424-34
 16. Raymundo IT, Bahmad F, Filho JB, Pinheiro TG, Maia NA, Oliveira CA. Intratympanic methylprednisolone as rescue therapy in sudden sensorineural hearing loss. *Braz J Otorhinolaryngol*. 2010 ;76(4):499-509
 17. Zernotti ME, Paoletti OA, Zernotti M, Martínez ME, Roques-Revol M, Prina AC. Intratympanic dexamethasone as therapeutic option in sudden sensorineural hearing loss. *Acta Otorrinolaringol (English Ed)*. 2009;60(2):99-103.
 18. Kara E, Cetik F, Tarkan O, Sürmelioğlu O. Modified intratympanic treatment for idiopathic sudden sensorineural hearing loss. *Eur Arch oto-rhino-laryngology*. 2010;267(5):701-07.
 19. Hong SM, Park CH, Lee JH. Hearing outcomes of daily intratympanic dexamethasone alone as a primary treatment modality for ISSHL. *Otolaryngol-Head Neck Surg*. 2009;141(5):579-83.
 20. Hamid M, Trune D. Issues, indications, and controversies regarding intratympanic steroid perfusion. *Curr Opin Otolaryngol Head Neck Surg*. 2008;16(5):434-40
 21. Ferri E, Frisina A, Fasson AC, Armato E, Giacomo Spinato, Amadori M. Intratympanic Steroid Treatment for Idiopathic Sudden Sensorineural Hearing Loss after Failure of Intravenous Therapy. *ISRN Otolaryngology*. 2011; 2012:1-6