



CASE REPORT

OPEN ACCESS

SEPTIC CAVERNOUS SINUS THROMBOSIS (CST) WITH BLINDNESS CAUSED BY ODONTOGENIC INFECTION – A CASE REPORT

Putri Permata Valentine¹, Yudhi Adrianto², Sita Setyowatie²

Correspondence: putrisiahaan917@gmail.com

¹Resident of Airlangga University-RS Universitas Airlangga, Surabaya, East Java.

²Staff of Neurology Department of Airlangga University-RS Universitas Airlangga, Surabaya, East Java.

Article History:

Received: December 19, 2022

Accepted: December 28, 2022

Published: January 1, 2023

Cite this as: Vancouver style

Valentine P P, Adrianto Y, Setyowatie S. Septic Cavernous Sinus Thrombosis (CST) With Blindness Caused By Odontogenic Infection – A Case Report. *Magna Neurologica*. 1 (1) January 2023:1-4.

ABSTRACT

Introduction: Septic cavernous sinus thrombosis (CST) is a rare thrombosis, but severe, causing damage to all nerves inside the cavernous sinus. The incidence rate of CST is estimated at two to four per million people per year. The symptom usually varies, gradually worsening, making diagnosis harder and potentially making permanent disability. Early detection and prompt treatment are very important to lower the morbidity rate.

Case: Tn. M had complained of multiple headaches attacks for 8 months ago before being admitted followed by diplopia. Complaints had worsened 3 months before with the loss of vision in the left eye. MRI showed left thrombosis sinus cavernous. The terrible headache was scaled 8-9 with VAS score. The patient's left eye was found proptosis palpebra, with anisocoria and mydriasis followed by no direct light reflex also indirect light reflex, visual acuity of the left eye is no light response, whereas the patient's right eye is normal. On the patient's left eye was found gaze palsy sinistra. The abnormal blood result was leukocytosis and thrombocytosis. The patient was given fondaparinux once a day with a dose of 6000 units subcutaneously for 5 days. After that, the headache was decreased significantly. The patient underwent 5 tooth extraction done by mouth surgeon after being discharged. The patient was given 20 mg rivaroxaban per day for three weeks, then 10mg per day for three months, and evaluated with MRV again.

Conclusion: CST is still very rare but very lethal and makes permanent disability on the patient. Through this case, we demonstrate the potential of tooth infection which leads to septic CST and caused ophthalmoplegia and blindness.

Keywords: Cavernous sinus thrombosis, blindness, proptosis

Introduction

Septic cavernous sinus thrombosis (CST) is a rare, but severe. It is a thrombotic process that can cause damage to all the nerves in cavernous sinus. Septic CST is usually caused by infection in the paranasal sinuses. Although uncommon, the source of infection can be from the ears, teeth and pharynx.¹ The most common etiology of visual loss in CST is optic neuropathy which can lead to orbital compartment syndrome, retinal ischemia and secondary atrophy due to vascular occlusion.² Because CST is so rare, that sources of statistical data on its incidence are few. The annual incidence of CST can be estimated from two to four per million people per year.³ Early detection of CST symptoms such as fever, headache, abnormalities in eye such as periorbital swelling, and ophthalmoplegia, is very important for a better prognosis. Although antibiotics can provide significant improvement in septic CST, the mortality rate remains at 20-30%, with serious ocular sequelae, especially blindness in 8-15% of cases.²

Therefore, early detection of the disease and adequate therapy are very important to reduce the possibility of complications.⁵

Case

A middle-aged man presented to our hospital with severe headache and blurred vision since 8 months prior to his visit. His complaints had worsened in the past 3 months and he went to a doctor several times but there was no improvement. In November 2020, he underwent cataract surgery of the left eye, yet it did not improve his vision. He was then referred to Ophthalmology Department of Airlangga Hospital. He underwent MRI revealing left CST so that he was referred to Neurology Department for Digital Subtraction Angiography (DSA) procedure. On examination, his headache was on pain scale of 8-9 but his vital signs were within normal limit. On eye examination, his left eye had palpebral proptosis, left pupil diameter of 5mm with negative light reflex, and his visual acuity was unresponsive to light. His left eye also had gaze palsy. Meanwhile his right eye has no abnormality (Figure 1).

The laboratory examination revealed leukocytosis (13.560/uL) and thrombocytosis (602.000/uL). Due to this high platelet count, we postponed the DSA procedure. Blood test re-evaluation was then performed showing higher increases in leukocytes (30.950/uL) and thrombocytes (806.000/uL) than those in previous examination. Thus the

DSA procedure was cancelled. We gave fondaparinux anticoagulant therapy once a day at a dose of 6000 unit subcutaneously for 5 days. During this therapy, we consulted this patient to Ophthalmology and Oral Surgery Department. Panoramic photo was performed demonstrating gangrene in his molars. The oral surgeon planned him for extraction after completing anticoagulant therapy. After being 5 days on fondaparinux, his headache subsided and he was discharged. A week after discharge, the patient visited Neurology outpatient clinic for evaluation, receiving rivaroxaban 20mg/day for three weeks, followed by rivaroxaban 10mg/day for three months. We planned the patient for re-MRV evaluation three months later as therapeutic evaluation.

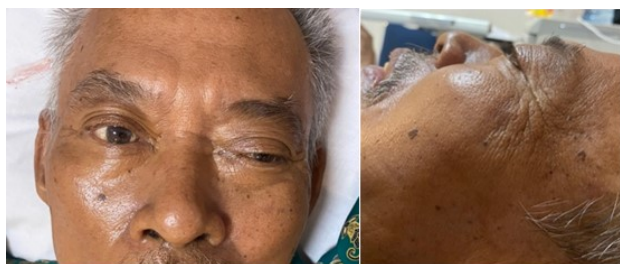

Figure 1. Proptosis of the patient's left eye

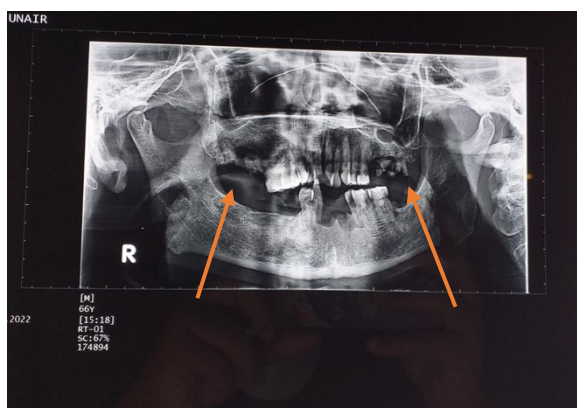
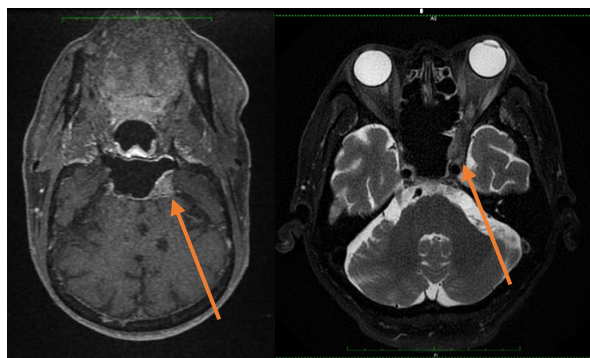


Figure 2. Panoramic Rontgen of the patient

Laboratory examination of the patient found leukocytosis (13,560) and thrombocytosis (602,000). Due to the risk of DSA being performed for patients with blood disorders such as thrombocytosis, the procedural DSA in these patients was postponed. The patient underwent re-laboratory examination, and found a higher increase in leukocytes (30,950) and platelets (806,000).



The patient was given fondaparinux anticoagulant therapy once a day at a dose of 6,000 units subcutaneously for 5 days. During the treatment, the patient was consulted to the Department of Ophthalmology and the Department of Oral Surgery. The Oral Surgeon found gangrene on teeth 18, 17, 26, 27, 28, 44 on the patient's panoramic photo examination and planned an action after the patient became outpatient (Figure 2). The patient's headache was reduced after 5 days of fondaparinux administration. The patient was discarded on the sixth day of treatment, and was planned for extraction by oral surgery at the Outpatient Polyclinic after anticoagulation was stopped for 5 days. The patient then went to the neurology department for control and received rivaroxaban therapy at a dose of 20 mg per day for three weeks, then continued with rivaroxaban at a dose of 10 mg per day for three months. The patient was planned for a repeat MRV examination three months later for therapeutic evaluation.

Discussion

Septic CST commonly results from infectious thrombosis, septic embolism, or sinusitis. This is a rare and potentially fatal diseases.² Its mortality and morbidity rate have persisted high, which are 13.6% and 23% because of delay in diagnosing.⁶

It should be noted that the cavernous sinuses are trabecular dural spaces that drain the ophthalmic, medial and cerebral veins as they are located on either side of the sella turcica, above and lateral to the sphenoid sinus, anterior to the superior orbital fissure and posterior to the petrosal portion of the temporal lobe.⁷ It also contains cranial nerves III, IV, V1, V2 and V1, the sympathetic plexus and the internal carotid artery.²

Cavernous sinus thrombosis can occur due to some factors, like:^{2,7}

1. Local spread, mainly from the facial and ophthalmic veins
2. Focal infections, such as sinusitis (the most common cause), especially sphenoiditis and ethmoiditis
3. Cellulitis and abscesses on the face, particularly within the danger triangle of the face, specifically at the corners of the mouth and tip of the nose)
4. Periorbital and orbital cellulitis
5. Pharyngitis
6. Tonsillitis
7. Otitis media
8. Dental infection and mastoiditis

The pathophysiology of septic CST is bacterial embolization and infection with organisms that cause thrombosis in which the infection can be trapped in the cavernous sinus. The path of communication between the right and left cavernous sinuses is through the intercavernous sinuses, anterior and posterior to the *cellae*, which allow the spread of thrombus and infection from one side to the other.⁷

Pressure on these structures and decreased venous drainage can lead to several abnormal findings, such as:^{2,7}

1. Diplopia due to partial or total external ophthalmoplegia, caused by compression of cranial nerves VI (abducens), III (oculomotor), and IV (trochlear). Abduction eye movement disorder is the most frequent and earliest finding, usually progressing to an inability to move the eye in all directions when other nerves are involved.
2. Internal ophthalmoplegia (non-reactive pupil) results from loss of sympathetic nerves from the short ciliary nerve (causing miosis) and/or from loss of parasympathetic nerves from cranial nerve III (causing mydriasis).
3. Numbness and paresthesias in the area of the eyes, nose, forehead and loss of corneal reflexes from the ophthalmic nerve, a branch of cranial nerve V (trigeminal).
4. Facial pain, paresthesias or numbness in the face may occur due to compression of the maxillary branch of cranial nerve V.
5. Infection in the cavernous sinus can spread to the central nervous system or to the lungs. The dural veins and cavernous systems do not have valves, while these veins can communicate with the dural sinuses and the cerebrum which can cause meningitis, dural empyema or brain abscess. The infection may also spread via the jugular vein into the pulmonary veins causing septic embolism or abscess, pneumonia or empyema.
6. Stroke can occur due to narrowing of the carotid artery, vasculitis or bleeding infarction followed by cortical vein thrombosis.
7. Hypopituitarism can occur due to ischemia or local spread or due to infection.

The diagnosis of CST is very challenging because of the non-specific and mild clinical manifestations, which include fever, proptosis, cranial nerve palsies in 80-100% of patients, decreased visual acuity, diplopia in 50-80% of patients, hemiparesis, and even seizures in 50-80% of patients.⁷ This patient has been complaining of a non-specific headache with blurred vision for months. This patient has also consulted with several doctors before, but due to the lack of supporting examinations in several health facilities, this patient did not receive an accurate diagnosis or adequate treatment.

The diagnosis of CST depends on a strong initial suspicion from a clinician.⁷ Laboratory tests that can be done to help diagnosing CST are complete blood count, hemostatic function including PT, aPTT, INR, and D-dimer. Additional tests for prothrombotic conditions include protein C, protein S, antithrombin deficiency, antiphospholipid syndrome, prothrombin G20210A mutation, and factor V Leiden. These examinations can be performed 2-4 weeks after anticoagulation administration.⁸ In this patient, laboratory examinations were performed and found leukocytosis and thrombocytosis.

Contrasted CT-Scan is preferred over plain CT-Scan, because plain CT-Scan gives a normal image in 25% of cases. CT scan with contrast shows an empty delta sign (4-28%), indicating a filling defect.⁸ MRV is the gold standard method for identifying filling defects in the cavernous sinus, as in this patient.⁷ In this patient an MRI was performed and found the presence of thrombosis in the cavernous sinus (Figure 3).

Cerebral DSA has the advantage of more detail in selectively viewing cerebral veins, especially for deep veins. It can distinguish hypoplastic or aplastic conditions/venous atresia, which is difficult to ascertain by CTV/MRV. Cerebral DSA examination is needed especially in suspected thrombosis involving relatively small cavernous sinuses such as the internal cerebral vein, thalamostriatum vein, and the basal vein of Rosenthal.⁸ Unfortunately, this patient could not undergo DSA because of the high level of blood, which is very risky for the occurrence of thrombus.

Anticoagulant therapy is administered to patients with CST with the aim of eliminating clotting and preventing the expansion of the clot. In this case, the blood flow to the cavernous sinus improved after anticoagulation, which is consistent with the literature. Stols et al. found improvement in 60% of cases of dural sinus thrombosis.⁹

The selection of the type of anticoagulant itself does not have specific guidelines accompanied by high scientific evidence that provides the best clinical outcome in CST cases. However, based on several meta-analytical studies, the use of low molecular weight heparin (LMWH) is preferred over unfractionated heparin (UFH). LMWH can be given subcutaneously for 5 days. Thereafter continued with warfarin for at least 3 months with a target INR of 2-3. Another option is heparin starting with a 3000 IU intravenous (IV) bolus then continued intravenously until the APTT is double the initial value but not 120 seconds, with a target APTT of 80-100 seconds.⁸ This patient received fondaparinux with dose of 6,000 units per day subcutaneously for 5 days. For 5 days, the patient experienced a significantly reduced headache. When the patient returned to the neurology outpatient clinic, we prescribed him with rivaroxaban at a dose of 20 mg per day for three weeks, then continued with 10 mg per day.

It should also be noted, for the management of septic CST, identifying of the source of infection is very important. Patients with CST and suspected bacterial infection are recommended to receive appropriate antibiotics and surgical drainage if there is a source of purulent infection associated with CST.⁸ On panoramic radiographs of the patient the source of infection was found in teeth 18, 17, 26, 27, 28, 44 (Figure 2). Therefore, we referred the patient to the oral surgery department for eradication of the source of infection, and this patient had five teeth extracted.

The prognosis for CST has improved, although morbidity remains high, and patients can develop complications such as meningitis, septic embolism, blindness and sepsis, which can lead to permanent disability. In this case, the patient was diagnosed late, which his left eye blind.⁷

Conclusion

Septic CST remains as a rare case. It can cause permanent disability and fatality. This case report demonstrates the potential of dental infection to develop into a septic CST resulting in ophthalmoplegia symptoms and blindness. Early diagnosis and adequate as well as appropriate management are required to avoid permanent complications.

Acknowledgement

The researchers would like to thank to Airlangga University General Hospital, Surabaya, East Java, Indonesia for facilitating this research.

References

1. Caranfa JT, Yoon MK. Septic cavernous sinus thrombosis: A review. Vol. 66, Survey of Ophthalmology. Elsevier Inc.; 2021. p. 1021–30.
2. Kim DH, Bautista SA, Mehta S, Briceño CA. Cavernous sinus thrombosis with bilateral orbital vein involvement and diffuse ischemic retinopathy. *Arquivos Brasileiros de Oftalmologia*. 2021;85(5).
3. Ali S. Cavernous Sinus Thrombosis: Efficiently Recognizing and Treating a Life-Threatening Condition. *Cureus*. 2021 Aug 20;
4. Mc P, Tadi P, Gupta M. Cavernous Sinus Thrombosis.
5. Ng EMC, Othman O, Chan LY, Bahari NA. Cavernous Sinus Thrombosis and Blindness Complicating Dental Infection. *Cureus*. 2022 Jan 17;
6. Astuti MB, Akib MN, Eka H. Ophthalmoplegia and Blindness after Septic Cavernous Sinus Thrombosis as Complications of Nasal Furuncle [Internet]. Vol. 25. 2021. Available from: <http://annalsofscb.ro>
7. Mira F, Costa B, Paiva C, Andrês R, Loureiro A. Cavernous sinus thrombosis. *Revista Brasileira de Oftalmologia*. 2014;73(3):182–4.
8. Sani AF, Bahar A, Pasaribu CMP, Andaka D, Usman FS, Nasution I, et al. Konsensus Nasional Neurointervensi. Surabaya; 2020. p. 45–56.
9. Idiculla PS, Gurala D, Palanisamy M, Vijayakumar R, Dhandapani S, Nagarajan E. Cerebral Venous Thrombosis: A Comprehensive Review. Vol. 83, *European Neurology*. S. Karger AG; 2020. p. 369–79.
10. Gordon DL. The diagnosis and management of cerebral venous thrombosis. In: *Handbook of Cerebrovascular Diseases, Second Edition, Revised and Expanded*. CRC Press; 2004. p. 605–35.